

CARTE ABSTRACTĂ



**MYOPIA DAY
CONFERENCE**

**CONFERINȚA
ȘTIINȚIFICO-PRACTICĂ
„ZIUA MIOPIEI”**

**12-13 Octombrie 2023
Complexul Sociocultural al Universității
str. Nicolae Testemițanu 25, Chișinău**

Editura ”ARVA COLOR”

Chișinău, 2023

COMITETUL DE ORGANIZARE:

Lilia Dumbrăveanu, dr. med., conf. univ., șef Catedră de Oftalmologie și Optometrie

Bîlba Rodica, dr. med., șef al Departamentului de Studii Medicale de Oftalmologie și Optometrie, Președinte al Asociației de Ortokeratologie și Management al Miopiei

Valeriu Cușnir, D.Hab. med, profesor universitar, Șef Clinică Oftalmologie, Președinte al Societății de Glaucom și Inflamație Oculară din Republica Moldova

Descrierea CIP a Camerei Naționale a Cărții din Republica Moldova

Conferința științifico-practică "Ziua Miopiei" = Myopia Day : conference, 12-13 Octombrie 2023, Chișinău : [Rezumate] = Abstract Book / comitetul de organizare: Lilia Dumbrăveanu [et al.]. – Chișinău : Arva Color, 2023. – 80 p. : fot., il. color.

Texte : lb. rom., engl. – [150] ex.

ISBN 978-9975-127-87-5.

617.7(082)=135.1=111

C 65

Editura „Arva Color” SRL

MD-2049, or. Chișinău, str. Mircești 22/4B,

tel.: 060 92 66 64



WELCOME

Respected Colleagues,

Greetings to the Scientific-Practical Conference "Myopia Day"!

We are delighted to have you here at this exceptional medical event that focuses on one of the most common vision issues worldwide - myopia. We all know how much impact myopia can have on the quality of life and eye health. This conference is a unique opportunity for ophthalmologists and optometrists to learn from world-class experts, explore the latest research and innovations in the field, and, most importantly, contribute to the fight against myopia. Together, we can make a significant change in eye health and the lives of our patients. Thank you for being here and joining this journey towards a clearer future for all!

Lilia Dumbrăveanu, Ph.D. med., associate professor, head of the Department of Ophthalmology and Optometry



WELCOME

Esteemed Colleagues,

Join us for the Scientific-Practical Conference "Myopia Day"!

It's a special moment where we bring together world-renowned experts in the field of myopia to share their knowledge and experience with the medical community in Moldova. Myopia affects millions of people worldwide, and this event is an important step in better understanding and managing this condition. For ophthalmologists and optometrists, this conference provides an invaluable opportunity to learn from the best and contribute to the development of medical practice. Thank you, speakers, for coming to Moldova to share your experience and knowledge. We are delighted to have you here!

Bîlba Rodica, Ph.D. med., Head of Medical Studies Department of Ophthalmology and Optometry, President of the Association of Orthokeratology and Management of Myopia



WELCOME

Dear Colleagues,

Welcome to the Scientific-Practical Conference "Myopia Day"!

We are thrilled to have you here in Moldova at this event dedicated to myopia - a vision issue that millions of people worldwide face. This conference is an exceptional opportunity for ophthalmologists and optometrists to share and gain up-to-date knowledge about myopia. Our experts in myopia have come from all corners of the world to share their experience and expertise, and this event is a unique moment for the medical community in Moldova. Thank you for coming to be a part of this initiative for a clearer future for all our patients!

Valeriu Cușnir, D.Hab.Med, university professor, Head of Ophthalmology Clinic, President of the Glaucoma and Eye Inflammation Society from Republic of Moldova

Scientific-Practical Conference with International Participation - "Myopia Day"

Organizing committee:

Lilia Dumbrăveanu, Ph.D. med., associate professor, head of the Department of Ophthalmology and Optometry

Bîlba Rodica, Ph.D. med., Head of Medical Studies Department of Ophthalmology and Optometry, President of the Association of Orthokeratology and Management of Myopia

Valeriu Cuşnir, D.Hab. med, university professor, Head of Ophthalmology Clinic, President of the Glaucoma and Eye Inflammation Society from Republic of Moldova

Scientific committee:

Lilia Dumbrăveanu, Ph.D. med., associate professor, head of the Department of Ophthalmology and Optometry

Bîlba Rodica, Ph.D. med., Head of Medical Studies Department of Ophthalmology and Optometry, President of the Association of Orthokeratology and Management of Myopia

Valeriu Cuşnir, D.Hab.Med, university professor, Head of Ophthalmology Clinic, President of the Glaucoma and Eye Inflammation Society from Republic of Moldova

Chiriac Vera, Ph.D. med

Cosula Cristina, DOO

Curca Stelian, DOO

CENTRUL MEDICAL OCULUS PRIM



Oferim servicii oftalmologice specializate pentru copii și adulți:

- Diagnostic performant;
- Tratament fizioterapeutic;
- Tratament ortokeratologic (lentile de noapte);
- Lentile sclerale rigide;
- Tratament laser;
- Tratament revoluționar terapeutic pentru keratoconus - Crosslinking UVTM-X Epi-On

Te așteptăm la Oculus Prim!

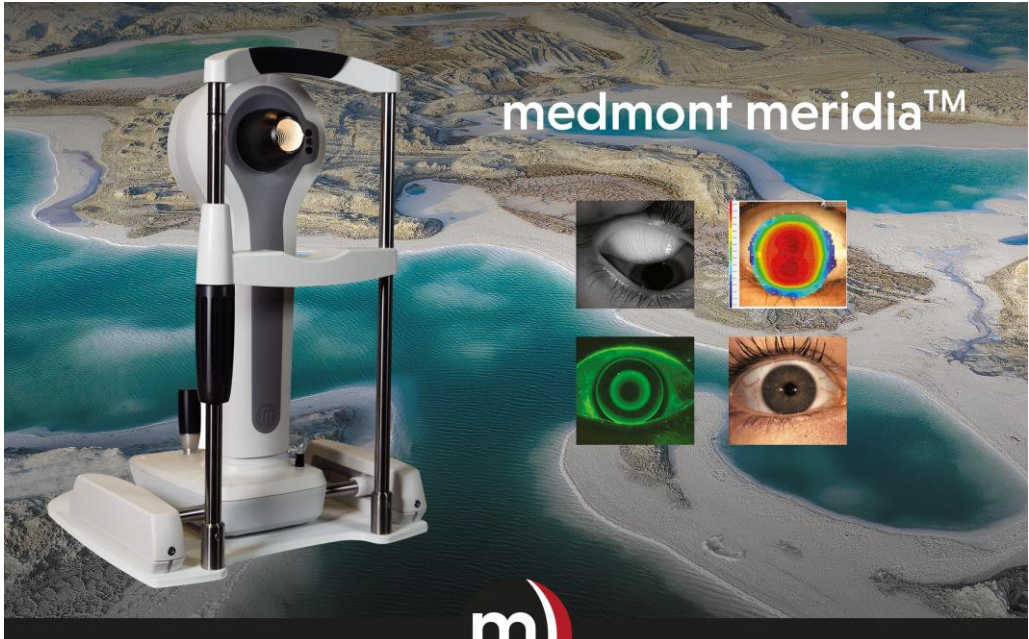060 21 11 60 | 022 83 70 60 | 022 83 70 63

Str. Alexandru cel Bun 108/1



LA STRAJA SANATATII TALE!

www.oculusprim.md



Tel +41 21 620 06 66

swisslens.ch/medmont-meridia-topograph/



SwissLens

Myopia management with **SwissLens**

simplicity without limits



Myopia management

Relax System

Range of contact lens designs with optimized **Hyperopic Defocus Control (HDC)** zone to treat **myopia progression**.

Thousands of myopic children already fitted with Relax lenses
CE Mark approval for myopia control in children aged 8-18.

Soft Contact Lenses



Myopia

Relax



Myopia



Astigmatism

Relax T

RGP Contact Lenses



Ortho-K

NightFlex Relax

Optimised



optic zone



Myopia

RelaxFlex



Myopia

ToriFlex Relax



Astigmatism

www.swisslens.ch




lens.info@swisslens.ch

SwissLens

www.swisslens.ch

Become a customer and give the
best to your patients



Scientific-Practical Conference with International Participation - "Myopia Day"

PROGRAM

12th October 2023

8:00-9:00 - Registration

LARGE CONFERENCE HALL

9:00-9:05 - Announcement of the "Handmade Mold of the Human Eye" Contest, Crina Aramă, Head of the Optometry Department, Association of Medical Students and Residents

9:05-10:45 - Seminar: "Understanding Refraction and Binocular Vision". Basic knowledge on physiological optics with knowledge and interpretation of what's happening from a clinical point of view." - Marino Formenti, Italy

10:45-11:00 - Coffee Break

11:00-13:00 - Seminar: "Understanding Refraction and Binocular Vision". Basic knowledge on physiological optics with knowledge and interpretation of what's happening from a clinical point of view." - Marino Formenti, Italy

13:00-14:00 - Lunch

LARGE CONFERENCE HALL

14:00 -16:00 Seminar:

- "Key Aspects in the Selection of Orthokeratology Lenses and When It Would Be Better to Abandon This Idea." - Olga Ryabenco,
- "Epitheliopathy in the Context of Wearing Orthokeratology Lenses: Various Forms." - Olga Ryabenco
- „Scleral lenses - indications, mechanism of action, impact on the ocular surface.“- Olga Ryabenco

16:00-16:15 - Coffee Break

SMALL CONFERENCE HALL, ET. I

16:15-17:15 Workshop "The contact lens - between innovation and comfort", Alcon

SMALL CONFERENCE HALL, EXHIBITION HALL, ET II

THE SCIENTIFIC SECTION OF THE FIALTOV INSTITUTE OF TISSUE THERAPY OF THE NATIONAL ACADEMY OF MEDICAL SCIENCES OF UKRAINE

14:00-14:20 - "Management congenital cataract and aniridia" - Bobrova N.F., Ukraine

14:20-14:30 - "Rare Pediatric Intraocular Tumors" - Bobrova N.F., Sorochynska T.A., Ukraine

14:30-14:45 - "Hereditary Cataract: Clinical Professors and Optical Results after Surgery" - Bobrova N.F., Romanova T.V., Ukraine

14:45-14:55 - "Pupillometry in Patients with Accommodative Esotropia" - Bushueva N.N., Senyakina A.S., Martiniuc S.V., Slobodianic S.B., Shakir Duhaer

14:55-15:15 - "Orbital Fractures in Children: Clinical Characteristics and Restoration Techniques" - Tronina S.A., Bobrova N.F., Ukraine

15:15-15:25 - "Remembering Ancient Diseases: Two Cases of Trachoma in Ukraine" - Bobrova N.F., Sorochynska T.A., Shylyk A.V., Ukraine

15:25-15:45 - "Reconstructive Surgery of Iris-Crystalline Diaphragm Injuries in Ocular Blast Trauma" - N. Ulianova, Ukraine

15:45-16:05 - "Clinical Case of Treatment for a Complex Binocular Injury Resulting from Combat Action" - Bondari N.I., Ukraine

16:05-16:25 - "Intermediate Results of Combined Surgical Intervention in Combat-Induced Ocular Injuries" - Sidac-Petretsaia O.S., Ukraine

16:25-16:45 - "Desperation Doesn't Heal: The Role of Appropriate Approach in Primary Surgical Management of Combat-Induced Ocular Injuries" - A. Curiliuc, Ukraine

16:45-16:55 - "Application of Spherical Orbital Implants for Enucleation and Evisceration after Mine-Explosive Injuries" - Chebotarov Ye., Sidak-Petretskaya O., Polyakova S., Pukhlik O., Ukraine

16:55-17:05 - "Experience of High-Frequency Coagulation of Biological Tissues in Enucleation for Uveal Melanoma" - E. Puhlic, N. Pasecinicova, V. Naumenco, E. Cebotareov, Ukraine

17:05-17:15 - "Treatment of Choroidal Melanoma (Transpupillary Thermo-therapy and Brachytherapy with Sr90/It90)" - Polyakova S., Chebotarov Ye., Tsukanova I., Drumi D.

17:15-17:25 - "Orbital Disease Frequency Based on Visits to the Filatov Institute of Eye Diseases and Tissue Therapy of the National Academy of Medical Sciences of Ukraine from 2010 to 2020" - Polyakova S.I., Chebotarev E.P., Ukraine

17:25-17:35 - "Malignant Neoplasms of the Scleral Conjunctiva and Treatment Results" - Safronencova I.A., Buico A.S., Elaghina V.A., Ukraine

17:35-17:45 - "Clinical Results of Intravitreal Aflibercept Administration in the 'Treat and Extend' Mode for Patients with Subretinal Neovascular Membrane in Chronic Central Serous Chorioretinopathy" - Custrin T.B., Ukraine

17:45-17:55 - "Application of Micro-Pulsed Laser Trabeculoplasty in the Treatment of Primary Open-Angle Glaucoma" - Nasinnik I.O., Ukraine

13th October 2023

8:00-9:00 – Registration

LARGE CONFERENCE HALL

9:00-9:30 - Opening Ceremony of the Conference

Lilia Dumbrăveanu, Ph.D. med., associate professor, head of the Department of Ophthalmology and Optometry

Emil Ceban, rector of USMF "Nicolae Testemițanu", D.Hab.Med, university professor, corresponding member of the Academy of Sciences of Moldova

Victor Lacusta, D.Hab.Med, university professor, academician of the Academy of Sciences of Moldova, head of the Department of alternative and complementary medicine

Bîlba Rodica, Ph.D. med., Head of Medical Studies Department of Ophthalmology and Optometry, President of the Association of Orthokeratology and Management of Myopia

Valeriu Cușnir, D.Hab.Med, university professor, Head of Ophthalmology Clinic, President of the Glaucoma and Eye Inflammation Society from Republic of Moldova,

Eugeniu Bendelic, D.Hab.Med, university professor, head of the Department of Ophthalmology

Oleg Crudu, M.D., Ph.D., Associate Professor, Director of the Municipal Clinical Hospital "Holy Trinity," IMSP

Moderators: Prof. Marino Formenti, Prof. Vera Serdyucenco, Prof. Valeriu Cușnir, Prof. Jaume Pauné

9:30-10:00 - " Understanding the visual abilities of the myopic child" – Marino Formenti, Italy

10:00- 10:10 – „The role of meridional accommodation in adaptation to astigmatism.” – Vera Serduchenko, Ukraine

10:10-10:40 - "The Role of Orthokeratology in Myopia Management" - Antonio Calossi, Italy

10:40-11:10 - "The Power of Defocus Rings in myopia

management. (The optimal methods in Orthokeratology to control the progression of myopia) " – Jaume Pauné, Spain

11:10-11:30 - **Coffee break**

Moderators: Ph.D Rodica Bilba, Olga Ryabenco, Prof. Juan Bolivar

11:30-11:45 – “RelaxSystem from SwissLens: Elevate Your Myopia Management Strategies”, Pierre Bremont, Switzerland

11:45-12:00 - " Myopia Rebound after Orthokeratology Lenses Discontinuation", Rodica Bilba, Moldova

12:00-12:30 - "Ortho-k in post LASIK. How to succeed", Juan Bolivar, Spain

12:30-12:50 - "Corneal Structure Modifications following Orthokeratology Lens Usage" - Ryabenco Olga,

12:50-13:00 – „ Vessels changes and myopia” Natalia Konovalova, Ukraine

13:00-14:00 – **Lunch**

LARGE CONFERENCE HALL

Moderators: Ph.D Lilia Dumbrăveanu, Ph.D. Vera Chiriac, Daniela Goicea

14:00-14:10 - **Sponsor Presentation, Alcon**

14:10-14:40 - " The Significance of Measuring Axial Length in Myopia" – Daniela Goicea, România

14:40-15:00 – „How to use combined therapies”, - Daniela Goicea, România

15:00-15:15- “Role of multifocal soft contact lenses in myopia management”- Adriana Stănilă, România.

15:15-15:30 - "Astigmatism/Keratoconus. Early Diagnosis." - V. Chiriac, Moldova

15:30-15:45 - "Scleral Contact Lenses for Children with Keratoconus." – Olga Ryabenco

15:45-15:55 – Prevalence of computer syndrom and progression of myopia among Ukranian students, Olga Guzun, Ukraine

15:55-16:15 - "Non-Contact Myopia Correction Method. Rodenstock Offers Maintaining High Visual Acuity." - Tanya Kuschel, Germany

16:15-16:30 - "Eyeglasses Lenses for Myopia Control MyCon (Rodenstock) and MyoJunior (LTL). Differentiated Approach in Prescription." – Elena Kisleacova

16:30-16:45 – **Coffee break**

16:45-17:45 Workshop „Orthokeratology Myopia Management Fitting with SwissLens Relax System and more”, Lisa Kurischev, Pierre Bremont

17.45-18.00 Closing ceremony

20.00 Gala Dinner, Casa Nunții Noroc, Sapphire Hall

Managementul Miopiei

- Lentile ortokeratologice
- Lentile moi Relax Myopia



LA STRAJA SANATATII TALEI

MYOPIA MANAGEMENT

THE PROBLEM OF DIAGNOSIS AND CORRECTION OF MYOPIA.

Burdeina G.I., Wenger L.V., Dyachkova Z.E., Shapovalova A.A.

Odessa National Medical University

Today it is known that the organ of vision has a leading place in the structure of morbidity takes myopic refraction. The problem of diagnosis and correction of myopia is relevant, in connection with a significant decrease in the uncorrected distance vision acuity and the appearance of characteristic asthenopic complaints.

Purpose: to identify clinical features of myopia and myopic astigmatism.

Methods. 35 patients (70 eyes) with myopia and astigmatism. A standard ophthalmological examination was performed. Uncorrected distance vision acuity in average was 0.52 ± 0.03 relative unit. Spherical component refraction was 0.5–1.5 dptr, astigmatic - from 0.25 to 2.0 dptr. Visual acuity with white correction is 1.0.

The results. Among the respondents, 65% use glasses. At the analysis of the value of astigmatic myopic refraction showed that that weak (up to 1.5 D - 85%) values are most often found, clear astigmatism (more than -2.0 D) is noted in 15% of cases. In case of simple myopic astigmatism is determined the tendency of more frequent distribution of direct astigmatism, at the same time visual acuity remains sufficiently high. Anomalies of refraction cause the need for constant adjustment, as in the absence of additional aids difficulties are created for the adaptation mechanism.

A significant role at the same time, the correct selection of optical correction plays a role. In 70% subjects were characterized by asthenopic complaints. With myopia for solution of accommodation tasks for close distance focus is carried out with the lowest costs of accommodation, therefore when choosing the optimal correction for close distance for patients with myopia requires an individual approach. The presence of a patient with visual strain with myopia requires carrying out optimal correction to preserve vision working capacity.

Conclusions. It is more common in people with astigmatic myopic refraction there are weak values of astigmatism. It is necessary for myopia optimal correction to preserve visual performance and achieving the level of professional ability.

PREDICTIVE FACTORS OF MYOPIA PROGRESSION

Boychuk IM.

It is believed that predicting the future development of myopia can help identify high-risk children for early targeted intervention to delay the onset of myopia or slow progression. Researchers have built and evaluated different short-sightedness prediction models based on different data sets, including output refraction or biometric data, lifestyle data, genetic features, and data integration.

Scientists are studying the ways in which the eye grows, how to modulate eye growth, whether there can be a pharmaceutical to control eye growth. Genetic, environmental and etiological factors that accompany the development of myopia in children 6– 10 years and in adults are also studied. (Karla Zadnik, Donald O. Mutti, et al., 1999) Now it is suggested that at or before age 6 starting first grade: cycloplegic refraction $\leq +0.75$ D – risk for subsequent myopia.

Myopia risk is significant if: $\leq +0.50$ D for ages 7 to 8; $\leq +0.25$ D for ages 9 to 10.

Whatever age the child comes for a screening we may get help from growth curves - charts that are available on the internet that depict normal range of refraction for that specific age, we can use myopia risk calculators. Known factors that influence growing of myopia are as follows: age, Genetics and ethnicity, educational activities and visual environment, time spent outdoors.

It is noted that little outdoor play, continuous hours of near-work (>45 minutes), working distance <30 cm are crucial in myopia development. Increasing outdoor time by 1 hr per week decreases the risk of myopia progression by 2%/

A large number of studies of the prognosis of myopia development concerns the assessment of optical factors and the anterior-posterior value of the axis of the eye. In the work of a professor Rykova SO., (2000) established correlation between the optical components of the eye and the volume of accommodation. Differences were found between myopic and hypermetropic eyes. Other authors (K. Zadnik & al) used the values of cycloplegic refraction error and three optical components of the eye in the prognosis of the beginning of juvenile myopia at least 1 year after baseline.

The prognostic value of the ratio is also established axial length / corneal radius

(Sensitivity, 68.9%; specificity, 65.8%). If Ratio is $\geq 3,02$, then progression is in 174 cases from 205, if ratio is <3,02 then 335 cases from 349 have progression. It was installed, that the most sensitive morphometrical OCT test for the progressive form of myopia is the thickness of the retina in the area of 3 mm - 77.3% (DI 66.2 -86.2%). The highest specificity of the method was found in the study of refraction rates -

93.75% (DI 79.2-99.1%) and the length of the eye axis 94.12% (DI 80.3-99.1%). Thus, it can be considered with a fairly high reliability that the progressive form of myopia will be observed in children with a retinal thickness (in the area of 3 mm) more than 246.3 μm , with refraction more than 4.5 dptr and anterior-posterior eye size larger 25.3 mm. It is established that the presence of deformation of the layer of pigment epithelium exceeding 40% the studied area, typical for progressive myopia. (Boychuk I.M., Gorbatyuk T.L.)

The research of our laboratory within the framework of the science research work in 1984-1986 children of school age No. 35 of Odessa established that depth vision for a long distance was worse than a year before visual acuity decreased.

So, the visual acuity was 1.0, and the depth vision threshold for long distance was much higher than the norm and was 50 mm compared to the norm of 27.8 mm, $p=0.002$. The connection between the pathology of the connective tissue of the whole body and the progression of myopia was noted by V.P. Filatov and further confirmed by the results of experimental, electron-microscopic, biochemical, immunological, and clinical studies by other authors.

(Филатов В.П., Скородинская В.В., 1953; Збандут Е.В.; Усов Н.И. 1978; Аветисов Э.С., Йомдина Е.Н., Винецкая М.И., Тарута Е.П., 1981- 2005;

Ферфильфайн И.Л. 1975-2005; Бушуева Н.Н., 1995-2005; Curtin B., 1990; Thompson F.B., 1996; Goldschmidt E.C.; Fledelius H.C., 1995, Cibulskaya T.Y.)

All these parameters can be used in the practical work of an ophthalmologist; pay attention to such children of the group of risk in further observation and in refinement of treatment.

LACRIMA ARTIFICIALĂ CU ACID HIALURONIC



oculus  **prim**

LA STRAJA SANATATII TALEI

COMBINED TREATMENT EFICACITY OF PRE-MYOPES AGED 11-14 YEARS WITH FAMILIAL FACTOR

Bilba Rodica¹, Victor Lacusta², Lilia Dumbraveanu¹, Cuşnir Valeriu¹, Chiriac Vera¹, Curca Stelian¹, Coşula Cristina¹, Spoiala Errica¹

1. Department of Ophthalmology and Optometry Nicolae Testemitanu State University of Medicine and Pharmacy, Chisinau, the Republic of Moldova
2. Departament of alternative and complementary medicine Nicolae Testemitanu State University of Medicine and Pharmacy, Chisinau, the Republic of Moldova
3. Medical Center "Oculus prim", Chisinau

Introduction: The International Myopia Institute defines pre-myopia as "a refractive state of an eye of $\leq +0.75$ D and > -0.50 D in children where a combination of baseline refraction, age, and other quantifiable risk factors provide a sufficient likelihood of the future development of myopia to merit preventative interventions."

Material and methods: Clinical retrospective study, that included 20 pre-myopes (40 eyes) aged 11-14 years with familial factor. The combined treatment (physiotherapy and anti-fatigue lenses-Rhein Vision's Facile) was applied for 2 years.

Results: In base group with familial factor, the spherical equivalent increased (from 0.51 to +0,01 D) after 2 years of treatment. The *vitreous chamber* depth increased (from 17,06 to 17,37 mm).

In control group with familial factor the spherical equivalent has increased (from +0,22 to -1.11 D) after 2 years of treatment. The *vitreous chamber* depth increased (from 16,45 to 16,90 mm) after 2 years.

Between the basic group and control group, it was determined the statistical difference ($p > 0.05$).

Conclusions: The combined treatment has been proved to be an efficient method of prevention of myopia.

COMBINED TREATMENT EFICACITY OF PRE-MYOPES AGED 6-10 YEARS WITH FAMILIAL FACTOR

Bilba Rodica¹, Victor Lacusta², Lilia Dumbraveanu¹, Cuşnir Valeriu¹, Chiriac Vera¹, Curca Stelian¹, Coşula Cristina¹, Spoiala Errica¹

1. Department of Ophthalmology and Optometry Nicolae Testemitanu State University of Medicine and Pharmacy, Chisinau, the Republic of Moldova
2. Departament of alternative and complementary medicine Nicolae Testemitanu State University of Medicine and Pharmacy, Chisinau, the Republic of Moldova
3. Medical Center "Oculus prim", Chisinau

Introduction: Myopia management is an exciting area with new research and technology advancements that will allow us to detect the pre-myope earlier and more accurately manage pre-myopia.

Material and methods: Clinical retrospective study, that included 20 pre-myopes (40 eyes) aged 6-10 years with familial factor. The combined treatment (physiotherapy and anti-fatigue lenses-Rhein Vision's Facile) was applied for 2 years.

Results: In base group with familial factor, the spherical equivalent increased (from 0.59 to -0.23 D) after 2 years of treatment, and the *vitreous chamber* depth increased (from 15,60 to 15,79 mm).

In the control group, aged 6-10 years with familial factor the spherical equivalent has increased (from +0,66 to -0.76 D) after 2 years of treatment. The *vitreous chamber* depth has changed (from 16,59 to 17,02 mm) after 2 years.

Between the basic group and control group, it was determined the statistical difference ($p > 0.05$).

Conclusions: Significantly higher frequency of myopia onset was determined in the control group (21% of the combined treatment vs 74% of the control).

THE POWER OF DEFOCUS RINGS IN MYOPIA MANAGEMENT. (THE OPTIMAL METHODS IN ORTHOKERATOLOGY TO CONTROL THE PROGRESSION OF MYOPIA)

Jaume Pauné

Orthokeratology is today the highest efficacy optical treatment in myopia control. Optic zone treatment shape and size in Orthokeratology is currently under high interest and deep study related to its efficacy in slowing down axial length growth in children. The corneal optical zone obtained by orthokeratology can be modified in size, shape, and power by changing the OK lens designs, which affects myopia progression and AL elongation. Smaller back optic zone diameter induces a reduced Plus Power Ring Diameter that slows AL elongation in a higher ratio than standard OK lenses. Decentered lenses also showed better myopia control. These optical changes are design dependent and they account for high order aberrations increase that may account for an optical signal that stops eye growth. Moreover, the pupil role is involved since the placement of the Plus Power Ring inside the pupil children's area shows an enhanced effect. Orthokeratology may be effective in slowing myopic progression for children and adolescents, with a potentially greater effect when initiated at an early age (6-8 years). Safety remains a concern because of the risk of potentially blinding microbial keratitis from contact lens wear.

ORTHO-K IN POST LASIK. HOW TO SUCCEED

Juan Bolivar

The usual problems that can arise in this type of case will be addressed. How to make an adequate patient selection. And once done, knowing what data should be assessed to start the fitting, and how the new technology could help us. In order to improve the final result, post-lasik ortho-k fitting must be approached in a different way than ortho-k in non-surgical eyes. It will show what are those differences that must be taken into account. All this will show the way to increase succeed rate in Post-lasik Ortho-k.

MYOPIA REBOUND AFTER ORTHOKERATOLOGY LENS DISCONTINUATION

Rodica Bilba¹, Valeriu Cusnir¹, Liliana Dumbraveanu¹

1. Department of Ophthalmology and Optometry, Nicolae Testemitanu State University of Medicine and Pharmacy, Chisinau, the Republic of Moldova

Abstract

Background: Myopia is labeled as one of the most common eye disorders, one of the most effective methods of its treatment being orthokeratological treatment. According to UNESCO, approximately 1.37 billion children in more than 130 countries globally are at risk of progressing myopia.

Material and methods: Our study aimed to determine the efficiency of the orthokeratological treatment in 120 patients (240 eyes) who wore OK lenses over 3 years. 40 patients (80 eyes) wore OK lenses uninterrupted; another 40 patients - interrupted orthokeratological treatment for 3 to 6 consecutive months in the third year and another 40 patients worn OK lenses intermittently, on average at least 3 nights per week, in the third year of surveillance. All groups were divided according to the degree of myopia (mild or moderate), age (6-17 years and 17-19 years) and the presence or absence of familial factor.

Results: Obtained data showed that the difference between the groups manifested in the third year of the study. In the group with mild myopia and 7-16 years of age who interrupted OK, the annual gradient of myopia progression increased statistically significant up to 69.5% from initial value, compared to the patients who applied OK intermittently and uninterrupted in the third year, this index was equal to 15.3% and 5% of the initial value, respectively, with a statistically significant difference ($p < 0,001$). Also, in cases of discontinued wearing of OK lenses, the annual gradient of myopia progression increased significantly more in the group having a familial factor. In the group with mild myopia and 17-19 years, the annual gradient of myopia progression was 33.3% in the group who interrupted OK lenses, compared with 10.5% and 3.4% in the group who applied OK lenses intermittently and uninterrupted, respectively, with a statistically significant difference ($p < 0,001$). Questioning the patients shows a high level of visual and psychological comfort in the groups which applied OK lenses continuously (99.6 points) and significantly less points (60.0 points) in the group who discontinued OK lenses.

Conclusions. The results of the study showed that discontinued wearing of OK lenses leads to an increase in the annual gradient of progression of myopia. We would expect progression to decrease with time naturally, but this 'rebound' effect led to the conclusion that OK should not be ceased before age 16.

Key words. Orthokeratology, lenses, discontinued, interrupted wearing.

THE INFLUENCE OF ORTHOKERATOLOGY ON TEAR BREAK-UP TIME IN PATIENTS AGED 7-16 YEARS

Bilba Rodica¹, Cuşnir Valeriu¹, Lilia Dumbraveanu¹

1. Department of Ophthalmology and Optometry Nicolae Testemitanu State University of Medicine and Pharmacy, Chisinau, the Republic of Moldova

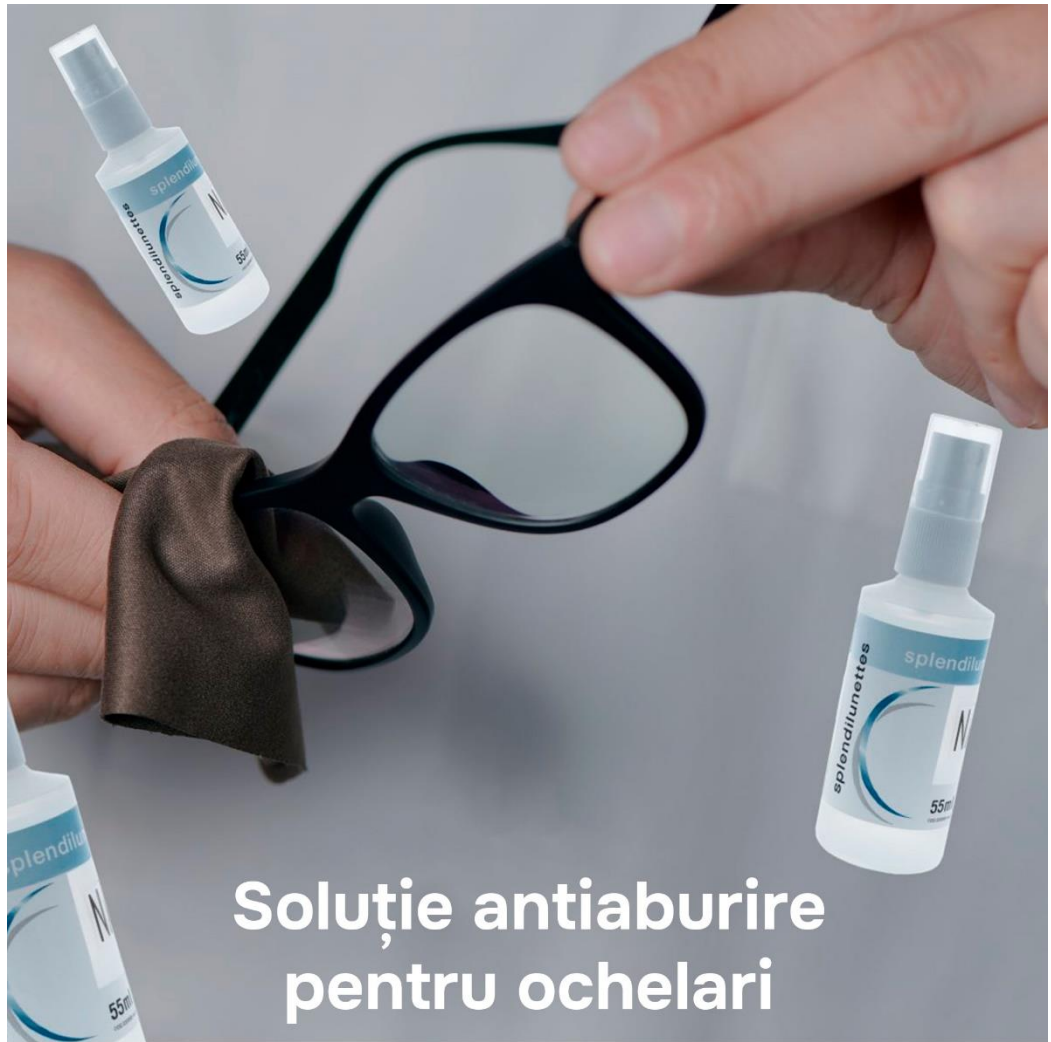Refractive therapy is one of the most effective contemporary methods of treatment and prophylaxis of the progression of myopia.

Aim: to evaluate the influence of refractive therapy on tear break-up time (NITBUT) in patients aged 7-19 years during a period of 36 months.

Method: Clinical prospective study, that included 80 eyes in patients aged 7-19 years with mild or moderate progressive myopia (mean $-2,54 \pm 2,22$ D). The treatment consisted of wearing night lenses for 6 to 8 hours during the night for 36 months. The NITBUT index was assessed before treatment, after 1, 7 and 14 days, 1, 3, 6, 12, 24 and 36 months of therapy.

Results: In patients that applied night lenses over 36 months the NITBUT index remained practically unchanged during the study, the difference between the minimum and maximum values being statistically insignificant ($p > 0.05$): 9.52 ± 0.22 seconds before treatment and 9.92 ± 0.25 seconds after 36 months, respectively.

Conclusion: Refractive therapy does not influence the tear break-up time in patients aged 7-19 years during a period of 36 months.



Soluție antiaburire pentru ochelari

oculus  **prim**

LA STRAJA SANATATII TALE!

THE INFLUENCE OF ORTHOKERATOLOGY AND PHYSIOTHERAPY ON THE EVOLUTION OF YEARLY MYOPIA PROGRESSION GRADIENT IN CHILDREN AGED 7-16 YEARS

Bilba Rodica¹, Victor Lacusta², Lilia Dumbraveanu¹, Cuşnir Valeriu¹, Chiriac Vera³, Curca Stelian¹, Coşula Cristina³, Spoiala Errica¹

1. Department of Ophthalmology and Optometry Nicolae Testemitanu State University of Medicine and Pharmacy, Chisinau, the Republic of Moldova
2. Department of alternative and complementary medicine Nicolae Testemitanu State University of Medicine and Pharmacy, Chisinau, the Republic of Moldova
3. Medical Center “Oculus prim”, Chisinau

Refractive therapy is one of the most effective contemporary methods of treatment and prophylaxis of the progression of myopia in children. A combination with physiotherapy has been proven to benefit the result even further.

Aim: to evaluate the evolution of yearly myopia progression gradient by spherical equivalent (YMPS) and eye globe antero-posterior axis length (YMPA) under combined treatment with refractive therapy and physiotherapy.

Method: Clinical prospective study, that included 80 eyes in patients aged 7-16 years with mild or moderate progressive myopia (mean $-2,52 \pm 2,25$ D). The treatment consisted of 3 years of refractive therapy combined with physiotherapy (electropuncture and ciliary muscle laser-stimulation during 10 days every 3 months).

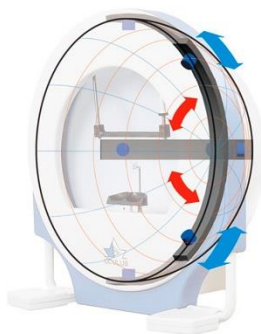
Results: In patients aged 7-16 years and mild myopia YMPS decreased down to 4.7% (0.04 ± 0.01 D; $p < 0.001$) from baseline (0.86 ± 0.12 D) after 3 years of treatment. In patients aged 7-16 years and moderate myopia YMPS has reduced down to 1.7% (0.02 ± 0.01 D; $p < 0.001$) from baseline (1.28 ± 0.22 D) after 3 years of treatment. In patients aged 7-16 years and mild myopia YMPA decreased down to 2.9% (0.01 ± 0.01 mm; $p < 0.001$) from baseline (0.34 ± 0.08 mm) after 3 years of treatment. In patients aged 7-16 years and moderate myopia YMPA has reduced down to 1.9% (0.01 ± 0.01 ; $p < 0.001$) from baseline (0.51 ± 0.12 mm) after 3 years of treatment.

Conclusion: Refractive therapy combined with physiotherapy reduces statistically significant the yearly myopia progression gradient by more than 95,0%.

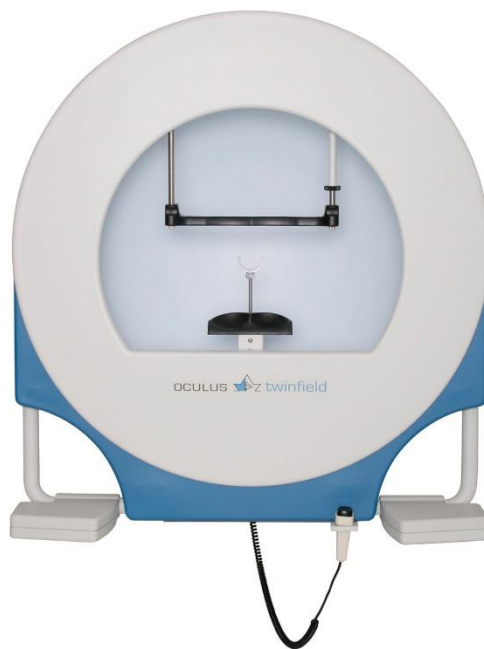OCULUS Myopia Master®
Refraction, Axial Length
and Keratometry



Distribuire aparataj oftalmologic



TWINFIELD 2 (PERIMETRU)



THE DIFFERENCE BETWEEN THE INFLUENCE OF PHYSIOTHERAPY AND ORTHOKERATOLOGY ON SPHERICAL EQUIVALENT AND ANTERO-POSTERIOR AXIS GROWTH IN CHILDREN AGED 7-16 YEARS

Bilba Rodica¹, Victor Lacusta², Lilia Dumbraveanu¹, Cușnir Valeriu¹, Chiriac Vera³, Curca Stelian¹, Coșula Cristina³, Spoiala Errica¹

1. Department of Ophthalmology and Optometry Nicolae Testemitanu State University of Medicine and Pharmacy, Chisinau, the Republic of Moldova
2. Department of alternative and complementary medicine Nicolae Testemitanu State University of Medicine and Pharmacy, Chisinau, the Republic of Moldova
3. Medical Center "Oculus prim", Chisinau

Contemporary myopia progression diagnosis is based on the values of spherical equivalent and antero-posterior axis growth. Physiotherapy and refractive therapy are two methods used to prevent further progression of this eye condition.

Aim: to evaluate the difference between the influence of physiotherapy and refractive therapy on spherical equivalent (SE) and antero-posterior axis (APA) growth in children aged 7-16 years during a period of 36 months.

Method: Clinical prospective study, that included 80 eyes in children aged 7-16 years with mild or moderate progressive myopia (mean $-2,50 \pm 2,24$ D), 50% of which were treated with physiotherapy, 50% - which applied refractive therapy.

Results: In children with mild myopia, after three years of physiotherapy, SE value increased by 1.4 times (from -1.54 ± 0.08 D up to -2.08 ± 0.13 D; $p < 0.001$). After 3 years of refractive therapy, SE value increased by 1.1 times (from -1.47 ± 0.08 D up to -1.68 ± 0.13 D; $p > 0.05$). The differences between both groups were statistically reliable ($p < 0.001$). In children with moderate myopia, after three years of physiotherapy, SE value increased by 1.3 times (from -3.75 ± 0.21 D up to -4.71 ± 0.26 D; $p < 0.001$) compared to therapy refractive, where SE increased by 1.1 times (from -3.8 ± 0.21 D up to -4.3 ± 0.26 D; $p < 0.05$). The differences between the data from both groups were statistically reliable ($p < 0.001$). In children with mild myopia, after three years of physiotherapy treatment, AAP value increased from 24.0 ± 0.08 mm up to 24.24 ± 0.13 mm ($p < 0.05$) compared with refractive therapy, where the same index increased from 23.92 ± 0.08 mm up to 24.0 ± 0.13 mm ($p > 0.05$). The differences between groups are statistically reliable ($p < 0.01$). In children with moderate myopia, after three years of physiotherapy, AAP value increased from 24.7 ± 0.21 mm up to 25.08 ± 0.26 mm ($p < 0.05$). In patients who applied refractive therapy, AAP value increased from 24.74 ± 0.21 mm up to 25.04 ± 0.26 mm ($p > 0.05$). The differences between groups are statistically reliable ($p < 0.01$).

Conclusion: Both, physiotherapy and refractive therapy stop the progression of myopia in children aged 7-16 years, but the refractive therapy shows statistically better results in comparison ($p < 0.001$).

oculus prim
LA STRAJA SANATATII TALEI

RollPed
Steril Göz Padi

RollOptik
Kapatici Göz Bandi

Pansament ocular steril adeziv

Swing
smart glasses

SwingFun kids

CONTROLUL MIOPIEI CU TRATAMENTUL COMBINAT ORTO-K SI MEDICAMENTOS IN PROGRESIA MIOPIEI.CAZ CLINIC.

Rotaru Irina, Clinica “Promed”, Chişinău, Republica Moldova.

Introducere: Prevalența miopiei este în continua creștere la nivel mondial și este în prezent recunoscută ca o problemă majoră de sănătate publică. Anual apar studii clinice și publicații științifice despre importanța controlului eficient al progresiei miopiei la copii.

În cadrul controlului miopiei, una dintre cele mai eficiente metode de tratament al acesteia, s-a dovedit a fi, conform studiilor recent publicate, tratamentul ortokeratologic și administrarea picăturilor cu atropina în doze mici de 0,01%.

Scopul: De a evalua efectele pe termen lung al ortokeratologiei în combinație cu soluție atropina în doze mici de 0,01% la copiii cu miopie progresivă.

Material și metodă: A fost urmărit cazul unei paciente cu vîrsta de 9 ani cu miopie progresivă, care anterior timp de un an de zile a fost sub tratament cu lentile de noapte. S-a observat o progresie a miopiei cu -0,75 D timp de un an, pe fondul tratamentului ortokeratologic și s-a luat decizia de a continua următorul an tratamentul orto-k în combinație cu soluție cu atropina în doza de 0,01% ,cite o picatura, o data pe zi, în ambii ochi. Pacientei i s-a examinat acuitatea vizuală corijată și necorijată, refracția obiectivă și subiectivă, keratometria, biometria (AAP), diametrul cornean, oftalmoscopia, topografia corneană. De asemenea pacienta a fost evaluată la intervale de 3, 6, 9 și 12 luni.

Rezultate și discuții: În perioada de urmărire a pacientei, s-a observat încetinirea progresiei miopiei cu stabilizarea indicilor refractivi și biometrici comparativ cu valorile inițiale, pe fond de tratament combinat, orto-k și soluție de atropina în doza de 0,01%. S-a determinat, după un an de tratament combinat, stabilizarea echivalentului sferic, cu o creștere de -0,25 D ambii ochi și menținerea indicilor biometrici (AAP). Acuitatea vizuală necorijată s-a menținut la aceleași valori ca și anterior inițierii tratamentului combinat. De asemenea, se menționează lipsa apariției efectelor adverse de la utilizarea atropinei în doza de 0,01%.

Concluzii: Conform cazului clinic evaluat timp de un an, s-a demonstrat că tratamentul ortokeratologic combinat cu picături de atropina în doza de 0,01% și-a dovedit eficiența și siguranța în încetinirea progresiei miopiei la copii.

EFFICIENCY OF ORTHOKERATOLOGY IN THE TREATMENT OF ACCOMMODATION DISORDERS IN PATIENTS WITH UNCOMPLICATED ACQUIRED MYOPIA

Bilba Rodica¹, Lilia Dumbravean¹, Cuşnir Valeriu¹, Chiriac Vera¹, Curca Stelian¹, Coşula Cristina¹, Spoiala Errica¹, Macarenco Ecaterina¹

1. Department of Ophthalmology and Optometry Nicolae Testemitanu State University of Medicine and Pharmacy, Chisinau, the Republic of Moldova
2. Medical Center "Oculus prim", Chisinau

Abstract: The study included 80 patients (160 eyes) aged 7 to 19 years (mean 15,2 ± 4.2 years) with low and medium myopia. All eyes were randomly divided into 2 groups of 80 each depending on the treatment, which in turn were divided depending on the degree of myopia and age. Patients of the main group applied orthokeratology (Moon Lens), the control group - optical correction. The study demonstrated the obvious superiority of the effect of orthokeratology on subjective indices of accommodation compared to optical correction.

Introduction: Myopia is labeled as one of the most common eye disorders, with a high incidence and prevalence worldwide. According to forecasts, in the near future (until 2020) there will be a considerable increase up to 2.5 billion of nearsighted people. Currently, according to the literature, one of the most effective methods of treatment and stopping the progression of myopia is orthokeratological treatment.

Aim: To evaluate the effectiveness of the orthokeratological treatment of accommodation disorders in patients with uncomplicated myopia acquired.

Material and methods: The study included 80 patients (160 eyes) aged 7 to 19 years (mean 15.2 ± 4.2 years), of whom 50% were 7 to 16 years of age (average 12.4 ± 2.3 years), and 50% - between 17 and 19 years (average 18.2 ± 0.5 years). All clinical cases were divided into two groups of 80 eyes depending on the treatment applied: patients who underwent orthokeratological treatment (with Moon Lens night lenses) and patients who applied monofocal aerial optical correction. Clinical cases were evaluated before treatment, after 1 year, 2 years and 3 years. In turn, each group was randomized according to the degree of myopia, age.

Results: In the group with low-grade myopia and the age of 7-16 years, the orthokeratological treatment determined the increase of the Relative Accommodation Reserve (RAR) after 3 years, (up to -5.14 ± 0.31 D - by -3, 02 D; p <0.001), compared to the optical correction, where the given index had statistically

insignificant dynamics (from -2.03 ± 0.21 D to -2.14 ± 0.22 D - with -0.11 D; $p > 0.05$). In the group with low grade myopia and the age of 17-19 years, after three years of orthokeratological treatment RAR changed insignificantly in both groups (up to -2.4 ± 0.22 D in the control group and up to -5.44 ± 0.38 D in the main group). In the group with medium-grade myopia and the age of 7-16 years, after three years of orthokeratological treatment, the RAR value increased by 4.4 times (up to -5.84 ± 0.26 D - by -4.51 D; $p < 0.001$), compared to the control group where the same index increased statistically insignificantly (up to -1.42 ± 0.11 D (with -0.01 D; $p < 0.001$)). In the group with medium-grade myopia and the age of 17-19 years, after three years of orthokeratological treatment, RAR increased (up to -5.8 ± 0.46 D), but it is much more significant compared to the control group, where the same index was -3.37 ± 0.37 D ($p < 0.001$). In the group with low-grade myopia and the age of 7-16 years, after three years of orthokeratological treatment, the Absolute Accommodation Volume (AAV) was 10.34 ± 0.78 D in the main group and 6.3 ± 0.58 D in the control group ($p < 0.001$). In the group with low-grade myopia and the age of 17-19 years, after one year of orthokeratological treatment, the AAV value was 10.12 ± 0.78 D in the main group and 6.61 ± 0.54 D in the control group, the differences between groups being statistically significant ($p < 0.001$). In the group with medium-grade myopia and the age of 7-16 years, after 3 years of orthokeratological treatment, the AAV increased 3.7 times compared to the initial data (up to 10.15 ± 0.84 D - by 5.83 D; $p < 0.001$) versus the control group, where the same index increased statistically insignificantly (up to 5.1 ± 0.44 D (by -0.83 D; $p > 0.05$)). In the group with medium degree myopia and the age of 17-19 years, after 3 years of orthokeratological treatment AAV was 10.32 ± 0.88 D), compared to the control group where the same index was 7.34 ± 0.67 D ($p < 0.001$).

Conclusions: The study demonstrated the obvious superiority of the orthokeratological treatment on subjective accommodation indices (RAR, AAV) compared to optical correction.

EVOLUTION OF MYOPIA PROGRESSION IN PATIENTS WITH ANISOMETROPIC AMBLYOPIA DURING ORTHOKERATOLOGICAL TREATMENT COMBINED WITH VISUAL THERAPY

Bilba Rodica¹, Lilia Dumbraveanu¹, Cușnir Valeriu¹, Chiriac Vera², Curca Stelian¹, Coșula Cristina², Spoiala Errica¹, Macarencu Ecaterina¹, Popușoi Cristina¹

1. Department of Ophthalmology and Optometry Nicolae Testemitanu State University of Medicine and Pharmacy, Chisinau, the Republic of Moldova
2. Medical Center "Oculus prim", Chisinau

Actuality. Myopia is labeled as one of the most common eye disorders, with a high incidence and prevalence worldwide. Currently, according to the literature, one of the most effective methods of treatment and stopping the progression of myopia is orthokeratological treatment. Anisometropic amblyopia was clinically identified in 1743 by George Louis Leclerc, Count of Buffon, who proposed a treatment applied even in the present. Anisometropic amblyopia continues to be treated by optical correction applied separately or in combination with occlusion or other therapies.

Aim: Assessment of myopia progression in patients with anisometropic amblyopia who have undergone orthokeratological treatment combined with visual therapy.

Methods. Clinical cases were divided into four groups of 16 eyes depending on the degree of myopia (small or medium) and the presence or absence of amblyopia.

Results. The application of the combined treatment for 3 years resulted in the cessation of myopia according to the spherocylinder from 0.94 D to 0.28 D in patients with amblyopia and mild myopia and from 0.93 D to 0.06 in those without amblyopia. The values of the antero-posterior axis had a similar dynamics, the differences being statistically significant ($p < 0.001$). In patients with moderate myopia its evolution had a similar dynamic, but more significant in patients without amblyopia: from 1.54 D to 0.06 D compared to patients with amblyopia - from 1.38 D to 0.28 D. After 3 years of study, the degree of anisometropia decreased from 3.43 D to 3.18 D ($p > 0.05$), the correlation between the annual gradient of progression of myopia and the degree of anisometropia being direct ($R^2 = 0.8846$). Corrected visual acuity depending on the degree of amblyopia had a positive dynamic as well: from 0.63 to 0.97 in cases with mild amblyopia and from 0.26 to 0.72 in cases with moderate amblyopia, the statistical difference between groups being highly true ($p < 0.001$). The absolute volume of accommodation had comparative dynamics and increased from 7.0 to 12.0 in patients with mild amblyopia and from 2.2 to 9.5 in patients with moderate amblyopia. The statistical differences between the results were highly true ($p < 0.001$).

Conclusions. It is rational to apply refractive therapy in the treatment and prevention of the progression of mild and moderate acquired uncomplicated myopia, with an average index of quality of life of 93.1%, versus 39.3% for optical correction.

MYOPIA CALCULATOR” APP

Authors: Bilba Rodica, Bendelic Eugeniu

Introduction. The exponential growth of myopic patients and the integration of information technologies in the medical system creates the need to implement programs for diagnosis, treatment and recommendations for these patients.

Purpose: Presentation of the application "Myopia computer".

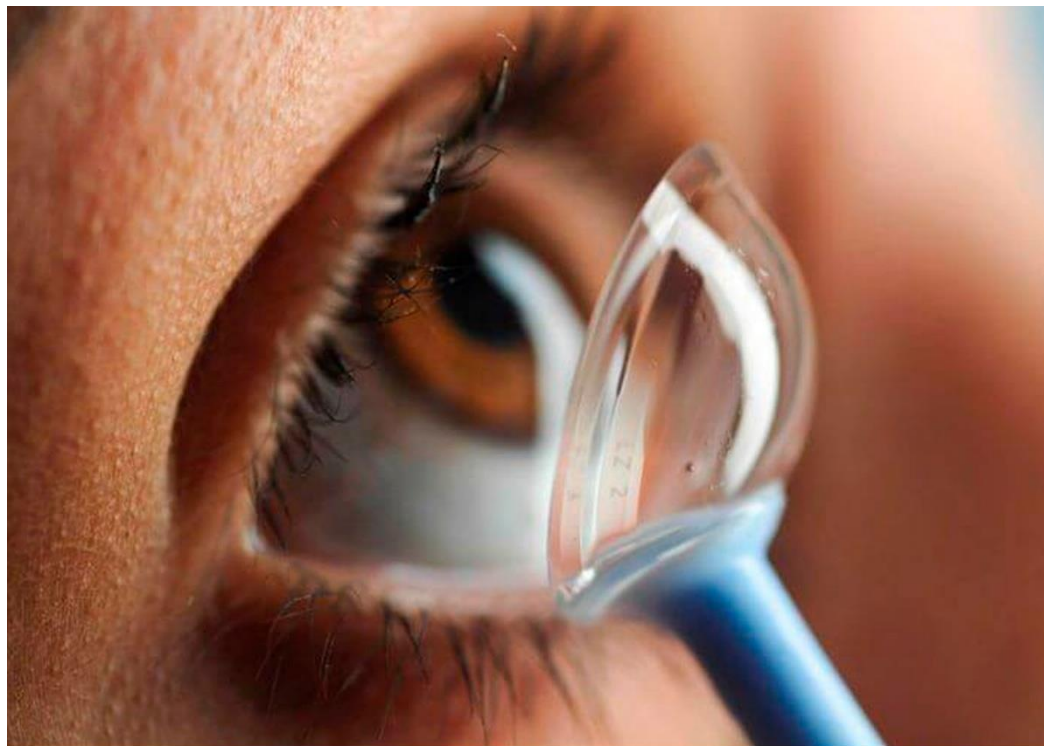
Abstract. The "Myopia Calculator" application is a program that allows users to find out about the evolution of the patient's myopia depending on the selected treatment, the degree of myopia, age, the annual gradient of progression of the initial myopia and family factor. The "Myopia Calculator" application can be installed in any gadget that supports the operation of the screen and allows the visualization of the numerical value and the graphical visualization of the result for reading and interpretation.

ASSESSING MYOPIA PROGRESSION BY MEASURING AXIAL LENGTH – FROM THEORY TO PRACTICE

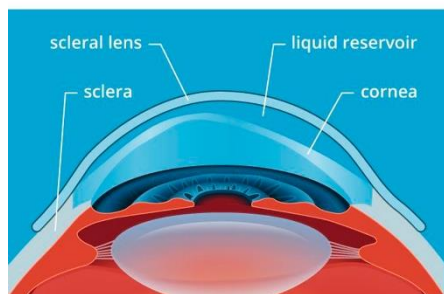
Daniela Goicea, MD, Focus Optic, Bucharest, daniela.goicea@focustopic.ro

The progresses in myopia management are related not only to treatment methods, but also to methods for assessing myopia progression. While refraction is concerning for children and their parents, as it is associated with vision deterioration, axial elongation is more important for practitioners, as it actually determines the risk of developing myopia related pathology. The fact that some myopia control methods, such as atropine, are not effective in axial elongation in spite of reducing refraction progression, enhances the need to measure axial length. Consequently, the axial measurement is currently considered to be the preferred method for assessing myopia progression.

Keywords: myopia, axial length



Lentile sclerale



Indicații și recomandări a lentilelor sclerale:

- Keratoconus
- Astigmatism sever
- Stare după transplant de cornee și incizii radiale
- Sindrom de ochi uscat sever
- Cicatrice posttraumatică a corneei
- Sindromul Stevens-Johnson
- Urmările arsurilor chimice
- Pemfigoid cicatricial



LA STRAJA SANATATII TALEI

HOW TO USE COMBINED THERAPIES

Daniela Goicea, M.D., Focus Optic, Bucharest, Romania

Usually, combined therapies consist of adding atropine in different concentrations to optical therapy, aiming to improve the efficacy of myopia control.

The presentation reviews the results of recent studies on combined therapies – mainly atropine plus orthok, soft multifocal contact lenses and myopia control spectacles. The second part copes with practical facts – when to use combined therapy, how to deal with high risk patients, and possible issues, with clinical examples from my practice.

Combined therapies are an option for children with progression on monotherapy, as well as a valuable alternative, especially in children with fast progression and risk of high myopia.

EFFICIENCY OF PSHYSIOTHERAPY IN THE TREATMENT AND PROPHYLAXIS OF UNCOMPLICATED ACQUIRED MYOPIA

Bilba Rodica¹, Victor Lacusta², Lilia Dumbravean¹, Cuşnir Valeriu¹, Chiriac Vera³, Curca Stelian¹, Cecan Mihaela¹, Coşula Cristina³, Spoiala Errica¹, Macarenco Ecaterina¹

1. Department of Ophthalmology and Optometry Nicolae Testemitanu State University of Medicine and Pharmacy, Chisinau, the Republic of Moldova
2. Departament of alternative and complementary medicine Nicolae Testemitanu State University of Medicine and Pharmacy, Chisinau, the Republic of Moldova
3. Medical Center “Oculus prim”, Chisinau

Introduction: Myopia is one of the most common eye pathologies, the prevalence of which is increasing globally. Physiotherapeutic treatment contributes to a better visual acuity, amplitude of accommodation, to the decrease in the speed of myopia progression.

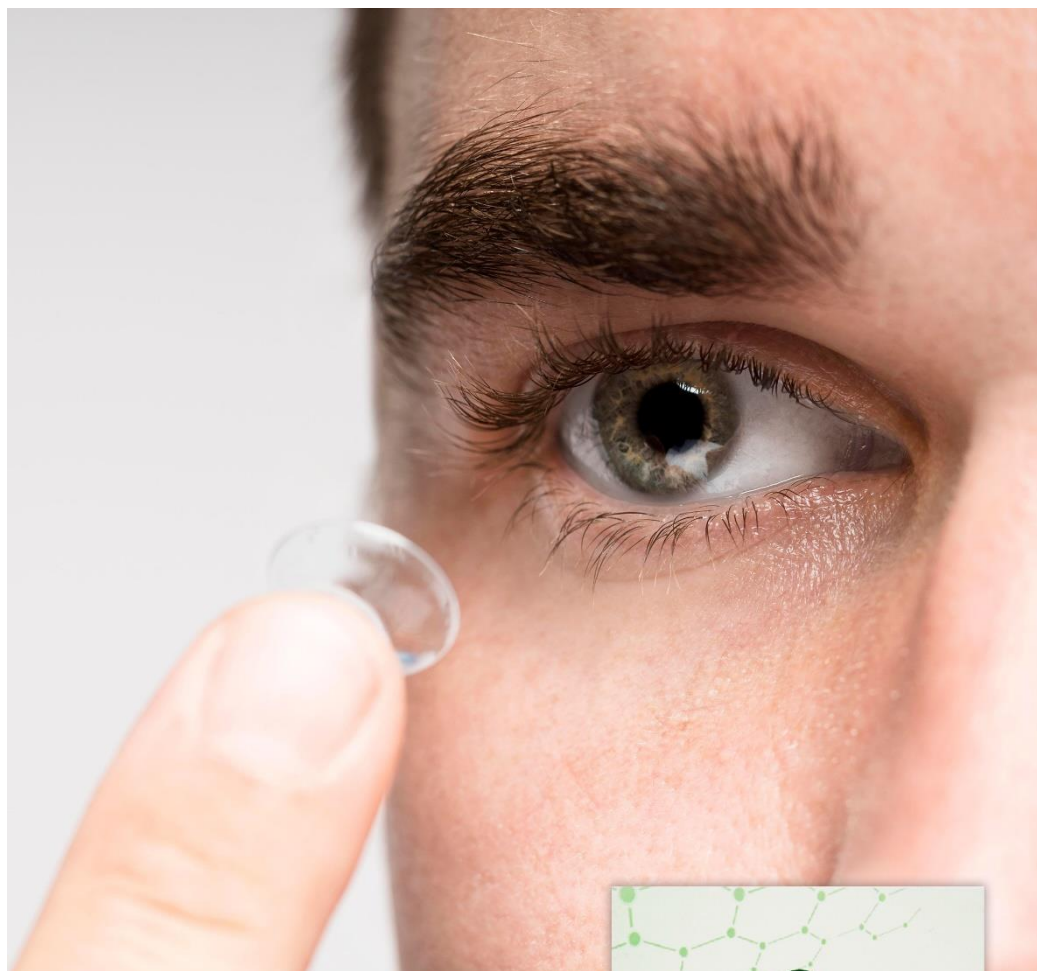Material and methods: Clinical retrospective study, that included 20 myopes (40 eyes) aged 6-11 years with low and medium myopia, randomized into two other groups depending on the presence or absence of the familial factor. The physiotherapy was applied for 2 years.

Results: The annual progression gradient according to the spherical equivalent in the group with low myopia and familial factor has decreased (from -0,68 D to -0,1875 D) and in the group with low myopia without familial factor has decreased (from -0,58 D to -0,1625 D).

The annual progression gradient according to the spherical equivalent in the group with medium myopia and familial factor has decreased (from -1,08 D to -0,3 D) from the beginning of treatment and in the group with medium myopia without familial factor has decreased (from -1,03 D to -0,075 D).

Between the group with familial factor and without, it was determined the statistical difference ($p > 0.05$).

Conclusion: The physiotherapeutic treatment leads to the decrease of the annual gradient of myopia progression by 80.49%



LENTILE NOI DE ZI
YALFRESH
CU ACID HIALURONIC



LA STRAJA SANATATII TALEI



CONTACTLESS METHOD OF MYOPIA CONTROL. MYCON BY RODENSTOCK

**Tanya Kushel, Rodenstock GmbH, Spectacles Consultant/Eastern Europe,
Central Asia, Baltic States, Germany**

The presentation summarizes the design features and benefits of the MyCon spectacle lens for myopia control, as well as a solution for maintaining extended fields of high visual acuity

SPECTACLE LENSES FOR MYOPIA CONTROL MYCON AND MYOJUNIOR. DIFFERENTIATED APPROACH IN PRESCRIBING.

**Chisleacova Elena - Ophthalmologist, a chief physician of optical chain
Eurooptica, Chisinau, Moldova**

**Bulici Svetlana - Leading ophthalmologist pediatrician of optical chain
Eurooptica, Chisinau, Moldova**

The presentation provides information on spectacle lenses for myopia control with different designs: axisymmetric (MyoJunior) and asymmetric (MyCon).

Aim: justify the need for a differentiated approach when choosing the design of spectacle lenses for myopia control.

Method: two clinical cases demonstrate optometric tests that are important to perform in all patients with progressive myopia.

Result: it is shown that correct interpretation of these tests leads to the correct choice of spectacle lenses.

Conclusion: the choice of spectacle lenses to myopia control should be differentiated. The decisive role in this case is played by the state of the accommodative apparatus of the eye, accommodation-convergence relationship, the presence or absence of binocular vision dysfunctions.

KERATOCONUS

ASTIGMATISM/KERATOCON: DIAGNOSTICUL ȘI TRATAMENTUL PRECOCE

Vera Chiriac, Rodica Bilba, Cristina Coisula, Popușoi Cristina - Clinica Oculus Prim

Sergiu Andronic, Ala Paduca - Clinica MCI

SUMMARY: ASTIGMATISM/KERATOCON: EARLY DIAGNOSTIC AND TREATMENT

We describe early diagnostic and microsurgical treatment of corneal ectasia - keratoconus and astigmatism of cornea. Results of the treatment dependence of a stage and evolution of keratoconus and pellucid corneal degeneration. Corneal Collagen Crosslinking with Riboflavin - CCC-R (UV -X) for corneal ectasia is established technique. Progression can be stopped by Corneal Collagen Crosslinking. For Astigmatism we prescribe correction with glasses or contact lenses and in final - laser treatment.

Keratoconul prezintă ectazie cronică, evolutivă, neinflamatorie a părții centrale a corneei. Afecțiunea bilaterală în 85%, interesează adolescentul sau adultul tânăr, incidența în raport cu gen nu este determinată, se denotă incidența familială. **Astigmatism** este viciu de refracție.

Actualitatea temei este determinată de creșterea incidenței keratoconului, cuprinderea un larg diapazon de vârstă - 8-74 ani, caracterul bilateral al afecțiunii (monolateral - 4,3-15%), evoluția progresivă, invalidizarea pacienților și are aspectul medico-social. Astigmatismul, care este deja prezent la naștere în unele cazuri este

Obiectivele studiului: Diagnosticul precoce afecțiunilor corneene prin utilizarea keratotopografiilor și pachimetriei. Definirea formulei adecvate de tratament și corecție optme.

Material și metode: Retrospectiv au fost examinați pacienți cu deficiență de vedere. Studiul a inclus explorările clinico instrumentale clasice cu accentul la examinarea keratotopografică. Metode de examinare - vizometria, biomicroscopia, keratometria, refractometria, keratotopografia, pachimetria corneei, esteziometria corneei. Diagnosticul se bazează pe: reflexul "Oil-droplet", schioscopie - umbra pupilară are o mișcare circulară, astigmometrie - mirele se deformează la schimbarea axului, keratoscopia - cercurile lui Placido ovale, neregulate, unghiul de prăbușire al axului orizontal, keratotopografia, biomicroscopie.

Rezultatele obținute și discuții: examinarea complexă a permis de a efectua tratament și corecție adecvată la pacienți pas cu pas pentru recuperarea acuității vizuale. Prezentarea cazurilor clinice.

Concluzii: Actualmente keratotopografia este strict necesară pentru un diagnostic precoce cert al afecțiunilor corneene. Analiza clinică a datelor keratotopografice permite alegerea unui tratament corect și corecție adecvată.

ANALIZA EFICIENȚEI CROSSLINKINGULUI TRANSEPITELIAL LA PACIENȚII CU KERATOCON

Șcerbatiuc Cristina¹, Eugeniu Bendelic¹

¹Catedra de Oftalmologie, USMF "Nicolae Testemițanu", Chișinău, Republica Moldova;

Introducere: Keratoconul este una din ectaziile corneene progresive, fiind caracterizată prin modificări neinflamatorii la nivelul colagenului stromal, ceea ce poate rezulta în protruzie și alterarea corneei centrale și paracentrale. Se manifestă de obicei în a 2-a sau a 3-a decadă a vieții prin miopie progresivă și astigmatism, initial unilaterală, apoi devenind bilaterală.

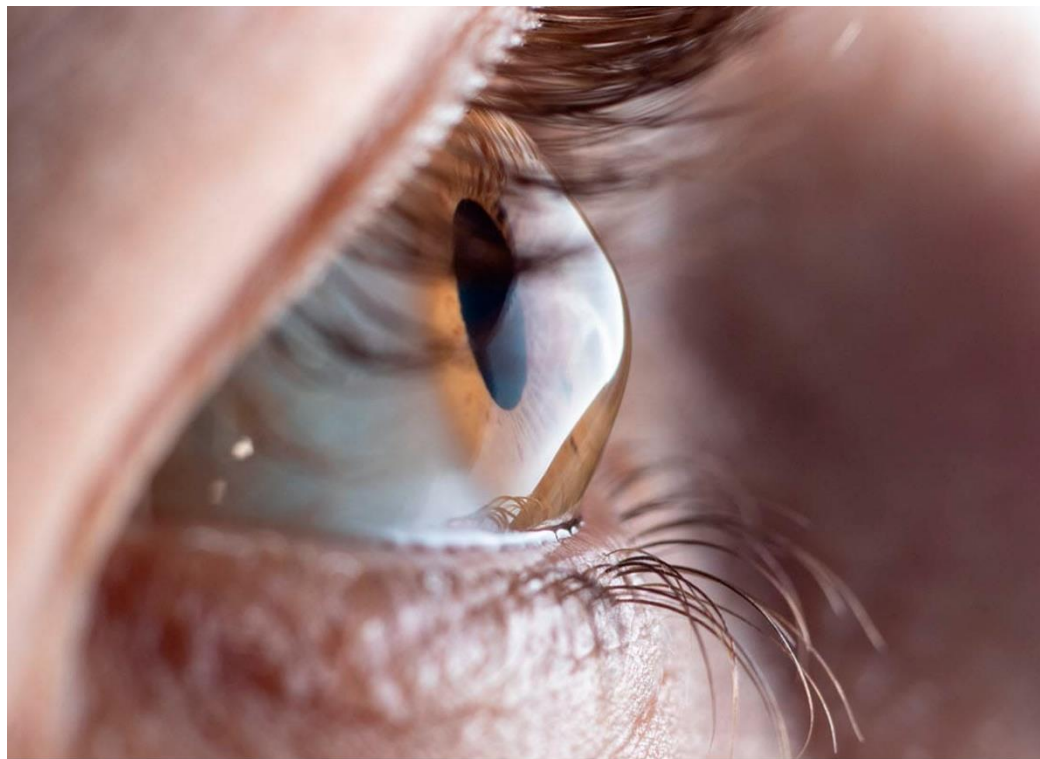În cadrul cross-linkingului cornean se utilizează riboflavina ca factor fotosensibilizant, cu expunerea la radiație UV-A, ce induce reacții fotochimice în stroma corneană cu formarea legăturilor covalente între moleculele de colagen.

Scopul: De a evalua efectele pe termen lung a crosslinkingului cornean la pacienții cu keratocon progresiv și vârsta mai mare de 18 ani.


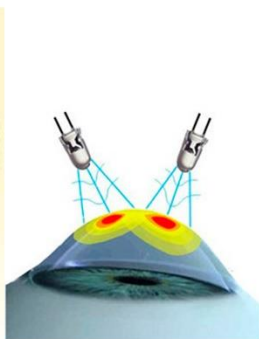
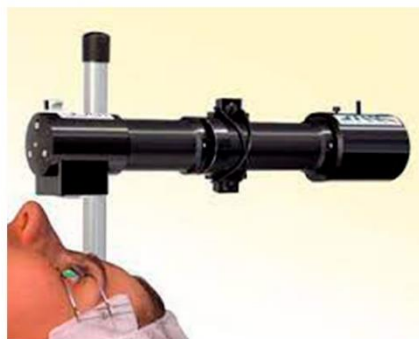
Material și metodă: Acest studiu a fost realizat pe 42 ochi a 26 pacienți cu keratocon progresiv pe parcursul a 2 ani, din martie 2019 până martie 2021. Procedura de crosslinking a inclus aplicarea soluției de riboflavină 0.1% cu conținut de 20% dextran timp de 15 minute înainte și înaintea de iradiere timp de 30 minute cu raze ultraviolete tip A (3 mW/cm). Pacientul a fost evaluat repetat la 3, 6, 9, 12, 24 luni după efectuarea procedurii. Pacienților li s-a examinat acuitatea vizuală corijată și necorijată, refracția cu evaluarea componentului sferic, max-K, (mean-K), grosimea corneei în regiunea centrală la 1, 3, 6, 12, 24 luni după crosslinking.

Rezultate și discuții: Toate măsurările keratometrice s-au îmbunătățit semnificativ în perioada de studiu. Comparativ cu valorile inițiale, s-a observat o dinamică pozitivă a parametrilor K_{max} , care au devenit statistic semnificative peste 12 și 24 luni după crosslinking. Echivalentul sferic a scăzut în timpul perioadei de studiu de la $-7.12D$ până la -5.82 peste 24 luni după crosslinking, de asemenea echivalentul cilindric a scăzut de la $-5.37D$ până la $-4.1D$. Acuitatea vizuală necorijată a crescut de la 0.51 ± 0.27 preoperator până la 0.66 ± 0.28 peste 24 luni după crosslinking.

Concluzii: Conform studiului nostru timp de 2 ani, procedura de crosslinking cornean la pacienții cu keratocon progresiv este eficientă, nu include riscuri majore, și poate elimina necesitatea cheratoplastiei la acești pacienți.



Cross-Linking epi-on



Tratamentul keratoconului



LA STRAJA SANATATII TALEI

CROSSLINKING UV™ – X EPI-ON

Bilba Rodica¹, Chiriac Vera¹, Borovic Djina¹, Coșulă Cristina¹, Popușoi Cristina¹

1. Medical Center “Oculus prim”, Chisinau

Keratoconus is a bilateral noninflammatory conelike ectasia of the cornea. Corneal Collagen Cross linking with riboflavin (UV™-X) strengthens the intrinsic biomechanical property of the cornea using ultraviolet A (UVA) and riboflavin 0,1%.

Aim: To evaluate the clinical usefulness of crosslinking – UV™ for stopping the progression of keratoconus.

Method: Clinical prospective study, that included 82 eyes with moderate or advanced progressive keratoconus (K: 48 – 72 D). Two techniques of treatment were performed: in 42 eyes - UV™-X epi-off and in 40 eyes - UV™-X epi-on. The first is accomplished with central corneal abrasion, riboflavin drops and exposure to UVA (365 nm, 3 mW/cm²) at 5 cm distance for 30 minutes. UV™-X epi-on is performed without desepitalization of the cornea with balanced solution of riboflavin instilled for 20 minutes and UVA exposure (365 nm, 9mW/cm²) for 10 minutes. Postoperative examinations were carried over the course of 1 day,1 week, 1, 3 and 6 months, including visual acuity, biomicroscopy, corneal topography, pachymetry, refractometry, keratometry.

Result: In all treated eyes, the progression of keratoconus was stopped. In 42 eyes (51,2 %) visual acuity was improved. The priority of UV™-X epi-on tehniqe results in absence of pain syndrome and fast postoperative recovery.

Conclusion: Crosslinking – UV™-X is a way for stopping the progression of keratoconus.

CROSSLINKING-ul TRANSEPITELIAL IN EROZIUNEA CORNEEANA RECIDIVANTA

Vera Chiriac, Cornelia Ceban, Rodica Bilba
Centrul Medical "Oculus Prim"

TRANSEPITELIAL CROSSLINKING IN THE RECIDIVANT CORNEAN EROZIA

Corneal Collagen Crosslinking (CXL) with Riboflavin and Ultraviolet-A (UVA) is a technique of corneal tissue strengthening that combines the use of riboflavin as a photosensitizer and UVA irradiation. The indication for the use of CXL is to stop the recidivate erozia

No recent studies for use crosslinking in recidivate erozia. Purpose of our study: assessing the effectiveness of Corneal Collagen Crosslinking in patients with recidivate erozia and strategy in the therapeutic management.

Actualitate. Indicația **Crosslinking-ul corneean-CXL (combinarea riboflavinei cu UV-A)** este stoparea recidivei eroziunilor corneene. Nu există studii cu privire la crosslinking-ul corneean la pacienți în special în eroziuni corneene recidivante.

Scopul studiului. Evaluarea eficacității crosslinking-ului corneean transepitelial la pacienții cu eroziunea corneeană recidivantă și conduita terapeutică în recidivă.

Metode. Studiul a inclus 9 pacienți - femei - cuprinse în vîrsta 24-31 ani - 9 ochi - cu recidivă de 2-3-4 ori - diagnosticate cu eroziunea corneeană recidivantă, inițial cauzate de un traumatism deepitelizant al corneei. A fost efectuat CXL epi-on, fără îndepărtarea epitelului cornean conform procedurii standartizate: s-a picurat riboflavin (Peschke TE) - timp de 20 minute, apoi expunere UVA(365 nm, 18 mW/cm²) pentru 5 minute. Examenul clinic a inclus acuitatea vizuală, biomicroscopia, topografia corneeană, pahimetria, refractometria, keratometria- la 1 săptămână, 1, 3, 6 luni, și anual.

Rezultate. La toți pacienții s-a păstrat acuitatea vizuală inițială. Nu a fost depistată recidiva eroziunii corneene post-operator timp de 4 luni- 3 ani.

Concluzii. Tratamentul adjuvant prin efectuarea crosslinking-ului transepitelial evita recidiva eroziunii corneene. Cunoașterea particularităților eroziunilor corneene recidivante permite elaborarea unei tactici terapeutice precoce pentru prevenirea recidivelor.

EFICENCY OF SCLERAL LENSES

CLINICAL CASES

Bilba Rodica¹, Dumbraveanu Lilia¹, Cuşnir Valeriu¹, Chiriac Vera¹, Cecan Mihaela¹, Curca Stelian¹, Coşula Cristina¹, Popuşoi Cristina

1. Department of Ophthalmology and Optometry Nicolae Testemitanu State University of Medicine and Pharmacy, Chisinau, the Republic of Moldova

Key-words: Scleral lenses, keratoconus, crosslinking, corrected visual acuity

Aim: To evaluate the effectiveness of scleral lenses in the correction of ametropia in patients with stabilized keratoconus.

Material and methods: Clinical retrospective study, that included 68 patients (99 eyes) with stabilized keratoconus after Crosslinking. Stage I was registered in 16 patients (16 eyes), Stage II-28 patients (45 eyes), Stage III- 24 patients (38 eyes).

Results: In patients with Keratoconus Stage I, the visual acuity corrected with glasses was 0.96, and with scleral lenses 1.0.

In patients with Keratoconus Stage II, the visual acuity corrected with glasses was 0.39, whereas with scleral lenses was 0.91.

In patients with Keratoconus Stage III, the visual acuity corrected with glasses was 0.28, while with scleral lenses was 0.79.

Conclusion: The visual acuity in patients with Keratoconus Stage I there was no statistically significant changes between correction with glasses and scleral lenses. The visual acuity corrected with scleral lenses in patients with Keratoconus Stage II and Stage III was 0.51 (230,8%) and 0.52 (285.7%) higher than in the case of monofocal optical correction application.



Laser-Eye-Center SRL
Intervențiile

1	Proceduri laser
	Intervenție laser în cazul glaucomului, iridoplastie, iridotomie
	Lasercoagularea retinei
	Laserdescizia cataractei secundare
2	Pleoape si conjunctiva
	Plastia punctului lacrimal
	Inlaturarea papilomelor, chisturilor, neoformatiunilor pleoapei/conjunctivei
	Inlaturarea pterigionului/pingueculi
3	Tratament chirurgical în patologia corneană, injectii i/vitriene, enucleatia
4	Tratament chirurgical în glaucom,
5	Tratament chirurgical strabismului
6	Tratament chirurgical în patologia cristalinului
	Implant de PF persecunda
	Extracția cataractei prin facoemulsificare cu implant de cristalin artif
	Extractia PF luxat + implant de PF
7	Tratament chirurgical în patologia polului posterior (vitrectomia, ect.)
	Tratament chirurgical în decolare de retina
	Tratament chirurgical în retinopatia diabetica
	Tratament chirurgical în patologia corpului vitros
	Tratament chirurgical în degenerescenta retiniana (gaura maculara)

În incinta Spitalului Polivalent Novamed (Novamed)

Sună

Adresă: Strada Tudor Strișcă 30, Chișinău 2038.

Telefon: 022 000 700

ABORDĂRI MICROCHIRURGICALE ALE PTERIGIONULUI RECIDIVANT

Autori: Victoria Fandofan^{1,2}, Ion Jeru¹, Uliana–Ariadna Bozul^{1,2}, Alex Nedelcu¹.

¹Catedra de Oftalmologie USMF “Nicolae Testemițanu”, ^{1,2}IMSP Spitalul Clinic Republican ”Timofei Moșneaga”, Chișinău, Republica Moldova.

Introducere: Pterigionul recidivant este o afecțiune degenerativă a suprafeței oculare constând în apariția unui strat triunghiular de țesut fibrovascular cu baza spre conjunctivă și vârful spre cornee după operațiile de înlăturare a pterigionului.

Scop: De a studia eficiența unei tehnici operatorii combinate în pterigionul recidivant stadiul II.

Metode: Studiul a inclus 12 pacienți (6 bărbați și 6 femei) cu pterigion recidivant stadiul II, cu vârstă cuprinsă între 20-71 ani, supuși intervenției microchirurgicale printr-o metoda combinată. Metoda constă din formarea unui lambou liber conjunctival, dreptunghiular 5x3 mm, inferior, paralimbal. Ulterior lamboul este fixat conjunctival, nazal în zona corpului pterigionului translocat în fornixul inferior. Este important ca lamboul conjunctival transplantat să posede o orientare limbală. La finele intervenției, subconjunctival se introduce 0,1 ml-5% 5-fluorouracil.

Rezultate: Reabilitarea postoperatorie a fost rapidă. Pe parcursul a 10-14 zile postoperator s-a instalat o iritare conjunctivală determinată de suturile de fixare ale lamboului conjunctival transplantat. Pe perioada menționată sunt indicate antibiotice, antiinflamatoare și lubrifiante. La 3 luni după intervenția microchirurgicală, la biomicroscopie semne ale recidivei pterigionului nu s-au depistat.

Concluzie: Metoda combinată efectuată în cadrul pterigionului recidivant, stadiul II este eficientă, sigură, determinată de lipsa recidivării pterigionului.

SCIENTIFIC SECTION OF THE FILATOV INSTITUTE OF TISSUE THERAPY OF THE NATIONAL ACADEMY OF MEDICAL SCIENCES OF UKRAINE

Orbital floor fractures in children: features of clinic and surgical treatment

Tronina S.A., Bobrova N.F.

SI “The Filatov Institute of Eye Diseases and Tissue Therapy of NAMS of Ukraine”

Odesa, Ukraine

Orbital floor fractures are among the most common facial fractures in pediatric patients (Roth et al, 2010; Soliman et al. 2023). This type of orbital fracture is a typical consequence of the orbital region direct blunt trauma, which can lead to prolapse of the orbital cavity contents into the maxillary sinus. If sufficiently large volume of orbital tissue is prolapsed and strangulated in the fracture zone, the typical clinical picture, including enophthalmos, hypoglobus, limitation of upward mobility of the eyeball, as well as functional visual disorders in the form of diplopia, develops. Various materials, such as high-density polyethylene, hydroxyapatite, titanium plates and meshes, as well as donor allo-implants and autologous implants were proposed to restore the integrity of the inferior orbital wall.

The aim of the work is to study the features of clinic of orbital floor fractures and surgical treatment using autologous tissues in children.

Material and methods. 9 children aged 7-15 years (mean age $11,1 \pm 2,4$ years) were operated on for orbital floor fracture at the Pediatric Ophthalmopathology Department of the Filatov Institut. All children complained to diplopia. Clinically in all cases the enophthalmos in the range of 5-7 mm, limitation of upward eyeball mobility, decreased visual acuity of the eye on the side of fracture were determined. CT examination of the orbit revealed the presence of fracture signs - a slit-like defect of the lower wall of the orbit with 3-4 mm diastasis of the edges or bone fragments of various sizes. Also the prolapse of a significant orbital fat fragment and also in 7 cases the inferior rectus muscle into the maxillary cavity with infringement in the fracture zone was noted.

Surgical treatment was performed in terms of 18-28 days after trauma, according to the time of applying to the institute. The restorative operation was performed by a transconjunctival approach using a fragment of the patient's auricular cartilage, which was taken from the posterior surface of the auricle at the first stage of the operation. After the fracture zone revision and sparing reposition of the prolapsed, the autcartilage plate was located under periosteum, overlapping the fracture zone, and fixed with sutures to the lower edge of the orbit. In cases before 21 days after trauma the process of orbital tissues repositioning was less difficult.

Results and discussion. The operation and postoperative period proceeded without complications. After subsiding of postoperative edema and inflammation the normalization of the position and motility volume of the eyeball was marked. The phenomena of diplopia gradually decreased until complete disappearance on the 6-18 days after the operation.

The control CT examination 3-6 months after the operation showed a stable position of the autocartilage plate implanted to the fracture zone, confirmed the absence of hernial protrusion of the orbital content.

Conclusion. The delayed terms of orbital floor fractures surgical restoration up to 14-21 days after injury in cases when early intervention was impossible are the optimal to avoid the soft tissues fibrosis development in the fracture zone, which worsens the conditions for safe reposition of orbital cavity contents.

The fracture restoration using autocartilage for plasty of the lower orbital wall has all the advantages of autoplasmic interventions, including the absence of the rejection reaction, danger of implant dislocation and extrusion. The proposed orbital floor fractures repairing technique is a highly effective alternative to the use of synthetic materials.

ULCERATIVE PSEUDOMONAS KERATITIS ASSOCIATED WITH CONTACT LENSES WEARING.

Olga Ivanova, Galyna Drozhzhyna.

The aim: To analyze cases of severe ulcerative Pseudomonas keratitis, associated with soft contact lenses (SCL) wearing.

Material and methods. In 2022 there were 28 patients (28 eyes) with severe infectious corneal inflammation associated with refractive SCL wearing.

Results. We have conservatively treated - 6 eyes, the average visual acuity increased from 0,17 ($M = 0.17 \pm SD 0,40$) till 0.5 ($M = 0.49 \pm SD 0,37$). In 3 cases was performed therapeutic keratoplasty, stepped penetrating keratoplasty - in 2 eyes, biological covering by method N.A. Puchkovskaya - in 1 case.

Conclusions. Ulcerative Pseudomonas keratitis is severe complication due to wearing SCL, it is registered in 56% of cases of bacterial keratitis associated with SCL wearing. As a result of the treatment infectious inflammatory process was stopped in all patients. It was possible to avoid urgent keratoplasty in 66% of cases due to the early (from 12 hours to 6 days) handling of patients in the hospital.

STANDARDISATION OF NEW EYE DROPS BASED ON POLYSACCHARIDES OF ALOE

Fesiunova G., Kisil S., Abramova G., Tsybuliak H., Volkova Yu.

State Institution “The Filatov Institute of Eye Diseases and Tissue Therapy of the NAMS of Ukraine” Odesa, Ukraine

Introduction. The development and expansion of the range of Ukrainian ophthalmic products, in particular, eye drops with a multivalent effect based on polysaccharides of Aloe, is of current interest and relevance. Acemannan is a polysaccharide that is contained in aloe plants. It has anti-inflammatory, antibacterial, antifungal, antioxidant, and neuroprotective effects, and activates the immune response, thus providing antiviral and antitumour activity, etc (Sierra-García G.D. et al, 2014; Mukherjee P. K. et al, 2014; Chang Liu et al, 2019; Hęś M. et al, 2019).

The development of eye drops based on the polysaccharides of aloe, which to a certain extent determine the high biological activity of the plant, requires a reliable and efficient method of standardisation following the requirements of Good Practice, verification, validation and justification of the manufacturing process.

Purpose. To develop the standardisation of new eye drops based on polysaccharides of Aloe (*Aloe arborescens*) in order to study the ophthalmic safety and specific activity of the new drug.

Material and methods. The study included pharmacological, chemical, physicochemical, pharmacognostic, pharmaco-technological, mathematical methods using an SF-46 spectrophotometer, an AXIS BTU210 analytical balance, centrifuge Opn-8UHL4.2, chamber and plates for thin-layer chromatography "Sorbfil" PTSH-AF-V, Hamilton microsyringe 10.0 μ l, software Spekwin 32, Qplot, ImageJ, Graph Digitizer, Plot Digitizer.

Results. The methods for determining the amount of acemannan, which is the main indicator of standardisation for new ophthalmic eye drops based on Aloe, were compared. The method of quantitative determination by dehydration of polysaccharides to hydroxymethylfurfural followed by spectrophotometric measurement at 490 nm was shown to have a sensitivity of 60 μ g/ml to 120 μ g/ml and to allow the introduction to the formula of a complex molar coefficient for converting standard monosaccharides (mannose and/or glucose) into acetylated aloe glucomannans. The introduction of a polycomponent molar coefficient will

improve the determination of the quantitative content of bioactive aloe polymers in the ready-to-use product.

It was shown that the thin-layer chromatography method improved by the software calculation of the amount and retention factor (Rf) may complicate the interpretation of routine analysis results, although being more informative for scientific research of a new drug.

The number of polysaccharides converted into acemannan is rationally carried out in the 1:4 ratio of aqueous extraction to ethyl alcohol. In this case, the experimental procedure for obtaining the number of polysaccharides is as close as possible to the analytical value recommended by the International Aloe Science Council ($\geq 5\%$).

Conclusions. A standard operating procedure was created for the analysis of plant raw materials as well as research samples of substance and ready-to-use product, which allows unifying quality analysis in the laboratory and predicting the potential pharmacotherapeutic activity of research samples, source materials and plant raw materials at the initial stages of new drug development.

Key words: aloe, tissue therapy preparations for ophthalmology, analytical methods to determine polysaccharides, acemannan, standardisation of plant raw materials

EFFECT OF A MIXTURE OF ETHYL AND METHYL ALCOHOLS ON THE ULTRASTRUCTURE OF THE OUTER LAYERS OF THE RAT VISUAL CORTEX

Molchaniuk N.I.

SI «The Filatov Institute of Eye Diseases and Tissue Therapy of the National Academy of Medical Sciences of Ukraine»

Odessa, Ukraine

Background. Alcohol surrogates containing methyl alcohol (methanol) have a significant toxic effect on the human body, primarily on the brain and visual organs. The reason for this is methanol, which resembles ethyl alcohol in smell and color, but is a strong poison. Consumption of up to 10 ml causes blindness, and consumption of up to 30–50 ml causes death. The purpose of our comprehensive research was to study the effect of a small dose of methanol and its combination with ethanol on the ultrastructures of the visual analyzer of experimental animals. The results of the study on the effect of these alcohols at the specified dose on the eyes of white rats have been published in scientific articles.

Purpose. To study the effect of a mixture of ethyl and methyl alcohols on the ultrastructure of the outer layers of the visual cortex (VC) of white rats.

Material and methods. The study was performed on 12 adult white Wistar rats weighing from 250 g to 300 g, divided into 2 groups: Study Group, experimental rats given a single intraperitoneal (IP) injection of a mixture of ethyl and methyl alcohols in a ratio of 3:1 with a dose of methanol of 0.75 g/kg of rat body weight; Control Group, rats given IP injection of 100 % methanol in a similar dose as in the Study Group. For rats, the LD50 effect of methanol is 9.5 g / kg of body weight. Animal manipulations and euthanasia were carried out in accordance with the European Convention for the Protection of Vertebrate Animals Used for Experimental and Other Scientific Purposes (Strasbourg, 1986). The ultrastructure of the molecular and outer granular layers of VC in the rats was studied using an electron microscope PEM-100-01 (Ukraine) in the period from 1 hour 10 minutes to 14 days after alcohol injection.

Results. At 1 hour 10 minutes and 3 hours after the IP injection of the alcohol mixture, elements of cytoplasmic edema of astrocyte processes that are in contact with capillaries and parts of nerve processes (NPs) located nearby were observed. Some of the nerve and glial cells underwent reactive changes. The structure of the capillaries was unchanged, but their lumen had osmophilic granularity.

After 3 hours, in addition to the above changes, there were nerve cells with chromatolysis and pathology of some mitochondria. The number of NPs with hydropic changes increased.

In the dynamics of the study (up to 14 days), the pathological changes in the studied structures of the central nervous system were progressing and referred mainly to the structures of the neuropil and glial cells. Among the nerve cells, only some had chromatolysis, mitochondrial pathology, and a reduced number of free ribosomes

and polysomes. It should be noted that on the 14th day, the depth of pathological changes was characterized by focality. In some areas of the central nervous system, the destruction of NPs plasmol and myelin sheaths of axons, alteration of organelles or complete devastation of the cytoplasm of nerve and glial cells was noted.

After the IP injection of methanol, the changes in the structures of VC were unidirectional with the changes in them after the IP injection of the mixture of alcohols, but in the dynamics of the study, they were somewhat more significant.

Thus, a single IP injection of a mixture of alcohols causes changes in the structures of the outer layers of the VC with hydropic dystrophy phenomena starting from 1 hour 10 minutes of observation, which leads to a violation of nerve impulse conduction and transport of nutrients. By day 14, changes in the EC progress and involve more nerve and glial cells and capillaries.

Conclusions

1. An intraperitoneal injection of a mixture of ethyl and methyl alcohols at a dose of 0.75 g / kg body weight in a rat causes, within the first 3 hours, hydropic degeneration of the processes of nerve and glial cells of the outer layers of the visual cortex, which are located mainly around capillaries.
2. In the dynamics of the study (up to 14 days), pathological changes in the studied structures of the visual cortex progress and involve nerve and glial cell bodies and capillaries.
3. Intraperitoneal injection of 100 % methanol at a dose of 0.75 g / kg body weight in the rat induces dystrophic changes in the structures of the outer layers of the visual cortex in the period from 1 hour 10 minutes to 14 days, but the depth of their manifestation in the dynamics of observation is more significant than after the use of a mixture of alcohols.

The ultrastructure of the outer layers of the visual cortex (VC) was studied in the period from 1 hour 10 minutes to 14 days after intraperitoneal (IP) injection of a mixture of ethyl and methyl alcohol in a ratio of 3:1 at a dose of 0.75 g / kg of rat body weight. Controls were rats that were given an IP injection of 100% methanol in the same dose as in the experimental group. It is shown that the mixture of alcohols causes, in the first 3 hours after the IP injection, hydropic dystrophy of the processes of nerve and glial cells of the outer layers of the VC, which are mainly located around the capillaries. By the 14th day of observation, the pathological changes in the studied structures of the VC progress and involve nerve and glial cell bodies and capillaries. After the use of 100% methanol in the dynamics of observation, deeper dystrophic and destructive changes in the structures of the outer layers of the VC develop than after the use of a mixture of alcohols.

OPHTHALMOLOGICAL COMPLICATIONS OF VIRAL INFECTION

Konovalova N.V., Khramenko N.I., Guzun O.V.

Institute of Eye Diseases and Tissue Therapy V. P. Filatov

National Academy of Sciences of Ukraine, Odesa, Ukraine

Odessa National Medical University

One of the most urgent problems of modern world medicine and the issue of humanity's survival is the high morbidity and mortality from viral infections. In recent decades, humanity has undergone serious trials.

The aim of the study. Study of the functional state of the visual analyzer (VA) and regional hemodynamics.

Materials and methods. All patients were examined according to the usual method: examination of visual acuity, field of vision, intraocular pressure, ultrasound diagnosis, biomicroscopy and ophthalmoscopy. Treatment: corticosteroids, non-steroidal anti-inflammatory drugs.

Result. As a result of the research conducted, in 19 patients (38.7%) who suffered a viral infection, in the absence of obvious structural changes in the organ of vision and with a high resolution (visual acuity 1.0), functional disorders were detected in the form of a violation of light adaptation in 2.3 times. Which was due not only to a violation of blood circulation both in the eye itself (a 10% decrease in volume pulse blood filling, an increase in the tone of blood vessels by 20%). And in the central part of the visual analyzer (an increase in the tone of large - by 54% and small - by 12% of the vessels of the basins of the internal carotid artery and vertebro basilar arteries). Also probably due to the neurotoxic effect of the viral agent itself and the phenomena of hypoxemia. A corrective effect (increase by 18%) of light sensitivity of the retina was noted after the course of treatment in 36 patients (73.4%). The main ophthalmological complications that arose in the post- viral infection period were mainly of vascular origin. According to the literature, it is known that cases of venous and arterial thrombosis develop in more than 30% of patients who have suffered a viral infection, of which venous thromboembolic conditions are the most common (27%). Our results confirm these studies. Timely started therapy leads to improvement of patients' condition and restoration of visual functions.

Conclusion Functional disorders were caused not only by impaired blood circulation both in the eye itself and in the central part of the visual analyzer, but also probably by the neurotoxic effect of the viral agent itself, hypoxemic disturbances of the homeostasis system.

Clinica IVEDERE Oftalmologică

+373 60 973 735
+373 60 338 894

Tratament specializat

Consultații

Optică medicală

Diagnostic computerizat

Intervenții chirurgicale



ivedere.md



contact@ivedere.md



CYCLOFUSIONAL RESERVES IN ORTHOTROPIC CHILDREN AND

THOSE WITH STRABISMUS

Serdiuchenko V.I., Degtyarova N.M., Hrushko Yu.V.

Filatov Institute of Eye Diseases and Tissue Therapy

Background: Fusional reserves play an important role in the development of full binocular vision. Although there is a general agreement among most authors on the values of horizontal and vertical fusional reserves, values reported for cyclofusional reserves vary widely, from 2-3° (Kanski, 2009) and 12-14° (Kashchenko, 2016) to 33° (Ellerbrock, 1954).

Purpose: To investigate the amounts of excyclofusion and incyclofusion obtainable with test objects subtending various angles in children with normal eye position and in those with cyclic strabismus.

Materials and Methods: Twenty-eight children (56 eyes; age, 5 to 17 years), including 16 (32 eyes) with orthotropia, normal visual acuity and binocular vision (group 1), 7 (14 eyes) with cyclic esotropia, mild hyperopia, best-corrected visual acuity (BCVA) of 0.6-1.0 and binocular vision with proper correction for refractive error (group 2), and 5 (10 eyes) with cyclic esotropia, hyperopia, BCVA of 0.7-1.0 and monocular vision with proper correction for refractive error (group 3), underwent examination. Cyclofusion was investigated with a synoptophore by turning one of the two test-objects clockwise or counterclockwise. We used paramacular test objects subtending 10° (degrees of arc) each, and parafoveal test objects subtending 2.5° each. Measurements for the right and left eyes were done.

Results: In children of group 1, the excyclofusion with 10°- and 2.5°-test objects was $13.0^{\circ} \pm 0.2^{\circ}$ and $9.6^{\circ} \pm 0.5^{\circ}$, respectively ($p < 0.001$), whereas the incyclofusion, $12.2^{\circ} \pm 0.8^{\circ}$ and $9.7^{\circ} \pm 0.5^{\circ}$, respectively ($p < 0.001$). In children of group 2 the excyclofusion with 10°- and 2.5°-test objects was $14.0^{\circ} \pm 0.8^{\circ}$ and $8.4^{\circ} \pm 0.5^{\circ}$, respectively ($p < 0.05$), whereas the incyclofusion, $13.4^{\circ} \pm 0.6^{\circ}$ and $8.8^{\circ} \pm 0.4^{\circ}$, respectively ($p < 0.05$). In children of group 3 the excyclofusion with 10°- and 2.5°-test objects was $4.7^{\circ} \pm 0.15^{\circ}$ and $3.6^{\circ} \pm 0.1^{\circ}$, respectively ($p < 0.05$), whereas the incyclofusion, $4.3^{\circ} \pm 0.1^{\circ}$ and $3.2^{\circ} \pm 0.1^{\circ}$, respectively ($p < 0.05$).

Conclusion: The cyclofusional amplitude was found to decrease with a decrease in the angular size of the test object in patients of three groups. Children with cyclic esotropia and monocular vision (group 3) demonstrated lower cyclofusional reserves on both paramacular and parafoveal test objects compared to children in the two other groups, which indicated their need for relevant exercises.

CLINICAL OUTCOMES OF A TREAT-AND-EXTEND REGIMEN WITH INTRAVITREAL AFLIBERCEPT INJECTIONS IN PATIENTS WITH CHOROIDAL NEOVASCULARIZATION IN CHRONIC CENTRAL SEROUS CHORIORETINOPATHY

Taras Kustryn, Oleg Zadorozhnyy, Illia Nasinnyk, Alla Nevska, Andrii Korol.

The Filatov Institute of Eye Diseases and Tissue Therapy of the National Academy of Medical Sciences of Ukraine

Background. Long-standing central serous chorioretinopathy (CSC) can show subtle signs that may suggest the presence of a type 1 (occult) choroid neovascularisation such as an indistinct late leakage on fluorescein angiography or the presence of fibrin or lipid deposition, as well as the presence of pigment epithelium detachment (Spaide et al., 1996). CNV in CSC has been reported with the incidence ranging from 2% to 18% in previous studies (Fung et al., 2012; Liu et al., 2016). Intravitreal anti-vascular endothelial growth factor (anti-VEGF) is the most widely used treatment option for CSC related CNV (Schworm et al., 2020).

Purpose: To evaluate the 12-month results of intravitreal aflibercept injections using a treat-and-extend regimen in patients with choroidal neovascularization in chronic central serous chorioretinopathy.

Materials: Participants in this prospective, interventional, single-center clinical study included 22 patients (22 eyes) with type 1CNV in chronic CSC. Intravitreal injections 2 mg/0.05 mL of aflibercept were performed on treat-and-extend (T&E) regimen. The primary objective was decimal best-corrected visual acuity (BCVA). The secondary objectives were complete resolution of intra- and subretinal fluid (ISRF), change in central retinal thickness (CRT)), change in subfoveal choroidal thickness (SFCT) on optical coherence tomography, interval between the last injection and the final visit, number of intravitreal injections and safety.

Results: Mean decimal BCVA showed a significant increase from 0.44 ± 0.35 to 0.58 ± 0.3 ($P = 0.01$) comparing baseline and Month 12. Complete resolution of ISRF was observed in 73% (16 eyes) during observation period. Mean CRT and SFCT decreased significantly from 321 ± 90 to 259 ± 93 μm ($P = 0.004$) and 364 ± 186 to 287 ± 124 μm ($P = 0.0002$) respectively, comparing baseline and Month 12. During all follow-up period mean a number of intravitreal injections of aflibercept were 7.5 ± 1.4 . Mean interval between the last injection and the final visit was 9.0 ± 4.1 weeks. There were no systemic adverse events and ocular side effects.

Conclusion: T&E regimen of intravitreal aflibercept is effective and safe method of treating patients with type 1 CNV in chronic CSC during 12 months follow-up.

TEMPERATURE OF THE SURFACE OF THE EYE IN THE PROJECTION OF THE CILIARY BODY IN RABBITS DURING THERAPEUTIC HYPOTREMIA AT 10° C

O.E. Dorokhova, O.V. Zborovska, O.S. Zadorozhnyi, V.V. Kolesnichenko

Odesa, Ukraine

SI "The Filatov Institute of Eye Diseases and Tissue Therapy of NAMS of Ukraine"

Introduction. In various fields of medicine, therapeutic hypothermia has been actively researched for the past few decades. In ophthalmology, there are only single works on therapeutic hypothermia.

Purpose. To study the dynamics of the temperature of the eye surface in the projection of the ciliary body in rabbits with transpalpebral therapeutic hypothermia of 10° C in normal conditions.

Materials and methods. The study was conducted on 24 Chinchilla rabbits (48 eyes). For therapeutic hypothermia (contact cooling) of the eye, a special thermoelectric device in the form of a monocular bandage was used for controlled local contact cooling of eye structures. The duration of hypothermic exposure was 30 minutes. The local temperature of the eyeball in the projection of the ciliary body was recorded every 10 minutes. After the end of the hypothermia process, the fixation of the local temperature of the eye was continued every 10 min for 40 min.

Results. Before hypothermia, the temperature of the surface of the eye in the projection of the ciliary body was on average 34.19°C, (SD 0.43). At 10 minutes, the temperature of the eye surface in the projection of the ciliary body decreased significantly to 29.64°C (SD 0.74). At 20 minutes, the temperature continued to decrease and was 29.38°C, (SD 0.72). But in comparison with hypothermia, there was no further statistically significant temperature drop within 10 minutes. And after 30 minutes of hypothermia, the temperature of the eye surface in the projection of the ciliary body decreased significantly by 0.45 °C $p=0.00$ and amounted to 28.93 °C (SD 0.48). At the same time, the temperature difference between the temperature of the eye surface at 10 minutes of hypothermia and at 30 minutes of 0.72 °C is significant.

After 30 minutes, the hypothermic effect was stopped, and we observed how the process of restoring the temperature of the eye surface would proceed. 10 minutes after the end of hypothermia, the temperature rose significantly to 32.8 °C (SD=1.26) $p=0.00$. But there is a significant difference between the initial temperature, which is 1.4 °C ($p=0.00$). 20 minutes after the end of hypothermia, the temperature rose significantly by 0.68 °C and reached 33.47 °C (SD=1.04), $p=0.00$. There is also a significant difference between the initial temperature, which is 1.4 °C ($p=0.00$). At 30 minutes, the increase in temperature stopped and there was an insignificant temperature drop to 33.32 °C (SD=1.09) $p=0.2$. And at 40 minutes, the temperature rose again by 0.06 °C, but insignificantly to 33.38 °C (SD=0.9) $p=0.5$. At the same time, there is a significant difference with the initial temperature before hypothermia of 0.82 °C $p=0.00$.

Conclusion. When studying the dynamics of the temperature of the surface of the eye in the projection of the ciliary body in rabbits during transpalpebral therapeutic hypothermia of 10°C in the norm at the 30th minute of hypothermia, the temperature was 28.93°C. During 40 minutes of observation after the end of hypothermia, there was no normalization of the temperature (34.19 °C) relative to the initial one. 20 minutes after the end of hypothermia, the temperature rose to 33.47 °C, and for another 20 minutes there were insignificant fluctuations by a few tenths of degrees. Taking into account the process of restoration of the eye temperature after the end of the hypothermia process, we confirmed theses about the autonomy of eye homeostasis.

A STRATEGY TO REDUCE DIGITAL EYE STRAIN OF UKRAINIAN STUDENTS

¹Guzun O., ²Bezdetko P., ¹Khramenko N., ¹Konovalova N., ¹Bushueva N.

¹The Filatov Institute of Eye Diseases and Tissue Therapy of the National Academy of Medical Sciences of Ukraine, Odessa, Ukraine

²Kharkiv National Medical University, Kharkiv, Ukraine

Abstract

An e-learning system will require additional time spent in front of a digital device. Spending long hours in front of these devices can lead to many ocular problems in students. Digital eye strain (DES) is the most common eye problem associated with prolonged digital devices use, characterized by symptoms such as dry eyes, itching, foreign body sensation, watering, blurred vision and headaches.

An analysis of the prevalence of Digital Eye Strain (DES) among Ukrainian students (320 students) during the Covid-19 pandemic was made.

A comprehensive examination and treatment of 70 students (140 eyes) with to DES at the age of 18 to 25 years, was carried out. Group 1 consisted of 26 students (52 eyes) and group 2 – of 44 (88 eyes). All students underwent a course of laser stimulation (LS) using a diode laser (10 daily sessions were performed on a CM-4.3 device, $\lambda = 650 \text{ nm}$, $W = 0.4 \text{ mW / cm}^2$, $t = 300 \text{ s}$). The students of the 2nd group were recommended additionally after LS to use for 3 months the vitamin-antioxidant complex Nutrof®Forte, 1 capsule once a day.

The prevalence of Digital Eye Strain with more than 6 symptoms reaches 84.4% in this sample of students, which is associated with a young age (18-25 years old), hard and long visual work and active use of digital gadgets and computers during distance learning. This high prevalence of DES underlines the importance of awareness raising and encourages the introduction of targeted screening for DES among students.

The course of treatment, including the intake of a vitamin-antioxidant complex of the AREDS formula with resveratrol and vitamin D₃, can significantly improve visual acuity, increase accommodation reserves, reduce spasm of intraocular vessels by normalizing the balance of the functioning of the sympathetic and parasympathetic parts of the autonomic nervous system and significantly reduce or even eliminate the existing Digital Eye Strain symptoms.

Key words: Digital Eye Strain, Computer Vision Syndrome, prevalence, diode laser stimulation, Nutrof®Forte, Covid-19

PUIPILOGRAPHY IN THE PATIENTS WITH ACCOMMODATIVE ESOTROPIA

Bushuyeva N., A., Senyakina A., S., Martynyuk S., Slobodiansky S., Dukhayer S.

The Filatov Institute of eye diseases and Tissue Therapy NAMN Ukraine? Odessa

Introduction. According to our data the widespread forms of accommodative esotropia (AE) are refractive (53,7±5,6%), nonrefractive (33,7±5,3%), combined (8,8±3,2%). The decompensate AE is a rare form of AE (3,8±2,1%).

The aim to study the visual functions and the state of accommodation – convergence – pupillary system (ACPS) in children with the most widespread forms of AE.

Materials and Methods Except of the standard ophthalmological examination (visometry, refractometry, accommodometry, strabometry, near convergence point's definition) the binocular pupillography was performed in 93 patients aged 6-18 years with refractive AE (48), nonrefractive AE (33), combined AE (12). The pupillography was performed using the apparatus "Oculograph OK-2" which was developed in Filatov Institute of Eye Disease (Patent №6232A61B3/00). We performed the computer registration of direct, consensual and accommodative convergent-pupillary reaction of leading eye and squinting eye without ametropia correction before and after light stimulation with the calculation of the area of the pupil, latency of pupil constriction. Moment of pupillography is shown in photo 1.

Results: Our results proved the data of other authors that refractive AE is characterized by high hypermetropia in both eyes (an average of 5,33 ± 0,36 D for the leading eye and 6,07 ± 0,32 D for squinting eye). In the case of nonrefractive AE the value of hypermetropia was the lowest: an average of 2,52 ± 0,39 D at the leading eyes and 3,51 ± 0,40 D at squinting eyes. Average degree of hypermetropia prevailed in patients with the combined AE: an average of 3,93 ± 0,56 D at the leading eyes and 4,32 ± 0,64 at squinting eyes. The values of squinting eyes' hypermetropia were larger than leading eyes in all cases. Most of them had the low value of anisometropia (an average of 0.75 - 2.0D). Patients with refractive AE and nonrefractive EA had the highest value of anisometropia (an average of 1,16 ± 0,17 D and 0,92 ± 0,13 D), and patients with combined AE had the lowest it's value (0,53 ± 0,2 D). Only 18,4 ± 7,5% of patients with refractive AE and 6,9 ± 3,9% of patients with nonrefractive AE had anisometropia from 2,25 to 4,0 D.

The visual acuity with optical correction below 0,3 took place of 55,8±7,6% patients with refractive AE, in 42,0±18,7% cases with combined AE, and in 33,3±9,1% children with nonrefractive AE. Convergence was normal in all cases of refractive and nonrefractive AE, but was weak in 42,8±18,7% patients with combined AE. Fusion in haploscopic condition was absent in 65,1±7,3% cases of refractive AE, in 51,9±9,6% patients with nonrefractive AE and in all cases of combined AE. Worth's

four dot test showed monocular vision in $88,4 \pm 4,9\%$ cases of refractive AE, in $85,1 \pm 13,2\%$ patients with combined AE and in $66,7 \pm 17,1\%$ cases with nonrefractive AE.

Analysis of pupillography shows that the investigated parameters of direct and consensual pupillary reactions of both eyes were almost identical in patients with different types of AE. But in conditions of background lighting the of squinting eyes' pupils were more narrow than the pupils of the most patients with any type of AE. The squinting eyes' pupils were statistically significant ($p < 0,05$) more narrow than the pupils of healthy eyes in all types of AE. The leading eye's pupil was statistically significantly more narrow in patients with nonrefractive AE during direct pupillary reaction and in patients with refractive AE during consensual pupillary reaction. Light stimulation led to decrease of both eyes' pupils' size as for direct as for consensual reactions. In any kind of AE the average areas for the direct reaction were in one and a half times greater than in healthy children. And the analogous data of pupils' consensual reactions in both eyes did not differ from that of healthy children. In comparison with healthy persons the significant lengthening of the latent period of the direct and consensual pupils' reactions were found on both eyes in any type of AE.

We evaluated the state of ACPS by the pupils' area, the latent period of pupils' restrictions time during moving of eyes from the remote object (100 cm) to approximate (10 cm). Average values of pupil area in both eyes of patients with any type of AE in condition of the ACPS' relaxation were almost two times lower than in healthy children. With the ACPS' strengthening these rates were almost the same and as in sick children as in healthy ones. The latent periods of the pupillary near reflex in both eyes were longer than in healthy children.

Conclusion: Direct and consensual pupillary reactions of both eyes have been weakened in patients with any type of AE in comparison with healthy children. It indicates on reduction of pupillary reactions lability. The presence of narrow pupils, elongation of the latent period of its' constriction in patients with any type of AE show that the ACPS of such patients is in a state of high tension, possibly due to accommodation. Disturbances of pupillary reactions indicate on reduction of lability, increase ACPS's passivity due to functional changes in brainstem.

MALIGNANT CONJUNCTIVAL NEOPLASMA OF THE SCLERA AND THE RESULTS OF THEIR TREATMENT.

Safronenkova I.O., Bouiko O.S., Yelagina V.A.

State Institution "The Filatov Institute of Eye Diseases and Tissue Therapy of NAMS of Ukraine", Odesa, Ukraine

Introduction: epibulbar conjunctival tumors on average make up about 9% of all tumors of the eye. Men (58% - 88%) of middle age (46 ± 18) get sick more often. Malignant conjunctival tumors of the sclera are mainly epithelial (squamous cell carcinoma) and melanocytic (melanoma). Their untimely detection, inadequate treatment and malignant nature of the disease can lead to loss of eye functions, loss of eyeball and often to the death of the patient.

Purpose: to evaluate the results of cryodestruction (CD) and radiocryosurgery (RC) treatment of malignant epibulbar neoplasms in the ophthalmic oncology center of the State University "The Filatov Institute of Eye Diseases and Tissue Therapy of NAMS of Ukraine".

Material and methods: 94 (76.4%) patients with epibulbar melanoma (EM) were treated, among them 51 (50.5%) men aged 18 to 88 years (median 51.3), 50 (49.5%) women aged from 26 to 87 years (median 57.3) and 29 (23.6%) patients with epibulbar carcinoma (EC), among them men - 24 (77.4%) aged 28 to 82 (median 66.3), women - 7 (22.6%) aged 35 to 74 (median 57). Cryodestruction (CD) was performed on 6 (6.0%) patients with EM and 10 (34.5%) patients with EC. Radiocryosurgical (RC) treatment was performed in 88 (93.6%) patients with melanoma and 19 (65.5%) - with carcinoma.

CD was performed by the cryogenic device based on a balloon-throttle microcryogenic system that provides low temperatures in the range of -90 - 120 °C. Radiotherapy was performed by brachytherapy with a Sr-90 radiation source, total focal radiation dose (SVD) = (200 ± 34.0) Gy.

Results: after CD of melanoma complete resorption of the tumor occurred in 5 (62.5%) patients, partial - in 2 (25%). 1 patient (12.5%) had recurrence within the scar. After CD of carcinoma complete and partial tumor resorption occurred in 11 (91.7%) and 1 (8.3%) patients, respectively. Thus CD in treatment of melanoma is 1.5 times more effective than in treatment of carcinoma. These differences are significant ($\chi^2 = 5.9$, $p = 0.04$). There were no immediate complications after CD. According to remote observations, recurrences were observed in 2 cases of melanoma and 2 cases of

carcinoma, 25% and 16.7%, respectively. Thus, no significant differences between the histological types of the tumor were found for this fact. After RC treatment complete and partial resorption of the tumor, both in melanoma and in carcinoma, was observed in almost equal proportions, respectively in 73 (78.5%) and in 20 (21.5%) and in 14 (73.7%) and in 5 (36.3%) patients and no significant differences between the histological types of the tumor were found for this fact.

After RC treatment in the EM group, tumor recurrences were observed in 18 (19.4%) cases, and in EC – in 9 (42.2%), that is, in carcinoma, recurrences were observed 3 times more often and these differences were significant ($\chi^2 = 6.9$, $p = 0.03$). Late complications during RK treatment (scleromalacia) were observed only in melanoma in 6 (5.9%) patients within 6 months to 5 years (median 9 months). Of them, 5 (4.9%) patients successfully underwent scleroplasty, one patient underwent enucleation. 4 (3.9%) patients with EM underwent exenteration of the orbit due to tumor recurrence and its growth into the orbit. After RC treatment with EC, 4 (12.9%) patients underwent enucleation due to tumor recurrence, development of secondary uveitis with hypertension, and growth of neoplasm into the eyeball. In 1 (3.2%) case, tumor growth into the orbit was observed and exenteration of the orbit was performed.

Conclusions: CD treatment of epibulbar carcinoma is 1.5 times more effective than CD treatment of epibulbar melanoma. RC treatment is equally effective for EC and EM. Recurrences of EM and EC after CD occur equally often. Recurrences of EC after RC treatment are observed 3 times more often than EM.

Key words: epibulbar tumors, melanoma, carcinoma, cryo- and radiocryosurgical treatment.

THE EXPERIENCE IN THE USE OF HIGH-FREQUENCY ELECTRIC WELDING OF BIOLOGICAL TISSUES DURING ENUCLEATION FOR UVEAL MELANOMA.

Pukhlik O., Pasychnikova N., Naumenko V., Chebotarov Ye.,

State Institution “The Filatov Institute of Eye Diseases and Tissue Therapy of the NAMS of Ukraine” Odesa, Ukraine

Introduction: according to the literature, enucleation of the eyeball in the treatment of intraocular tumors is carried out in 12.3 - 59.0% cases. Eyeball removal operations account for about 9.4% of all ophthalmic surgeries. During the treatment of these patients, the intra-operative and postoperative complications can take place. Existing methods for enucleation of the eyeball do not adequately prevent the development of these complications. The original electric instruments for enucleation of the eyeball were developed in the Filatov Institute of eye diseases and tissue therapy on the basis of the ophthalmooncology department in collaboration with the Institute of electric welding, as well as the method of high-frequency electric welding of biological tissues using the device EK-300M1 (Ukrainian patent No. 46981), which allows to achieve dissection, hemostasis and soft tissue connections.

Purpose: to evaluate the effectiveness of the high-frequency electric welding of biological tissues using for enucleation of the eyeball due to uveal melanoma.

Material and methods: the experimental and clinical studies were conducted in the development of enucleation techniques using the electric welding. In the study group of rabbits (20 rabbits) enucleation was carried out using the electric welding, in the control group of animals (8 rabbits) - according to the standard method. Animals were removed from the experiment immediately after surgery, after 7 days and a month later for histological examination and for electron microscopy, immediately after surgery, after 5 days and after 9 days. Postoperative edema of the orbit tissue, the condition of the sutures, and the amount of serous hemorrhagic secretion from the conjunctival cavity were evaluated. The clinical studies were also conducted in 79 patients with uveal melanoma, of which 59 patients aged 63.0 ± 10.5 years with uveal melanoma who underwent enucleation using the electric welding. The control group consisted of 20 patients with uveal melanoma aged 61.5 ± 8.6 years, who underwent enucleation according to the usual method.

Results: the experiment found that the electric welding in the mode of tissue connection leads to the closure of the conjunctival wound surface occurs as a result of fibrin prolapse, followed by epithelialization of the surface and fibrotization of subepithelial tissues. A conglomerate is formed from destroyed tissue elements, denatured proteins, collagen fibrils, and also a thin fibrillar “felt-like” material that “sticks” to the wound surface of the damaged tissue.

It was established in the experiment that when using the electric welding in the mode of tissue dissection, cutting occurs with simultaneous coagulation of blood vessels, and a narrow strip of dry necrosis is formed at the site of exposure. The using of the electric welding in the cutting mode made it possible to minimize bleeding at the intersection of extrabulbar muscles and the optic nerve, which excluded the tamponade of the orbit and reduced the time of surgery by an average of 6.6 minutes (18.4 + 3.1 in the study and 25.0 + 2,0 minutes in the control group, P <0.00001).

Conclusion: the using of the electric welding of biological tissues in conjunction of the conjunctival tissue allows achieving a strong connection of its edges, which excludes the procedure for applying and removing sutures.

Key words: the high-frequency electric welding of biological tissues, enucleation, uveal melanoma.

THE FREQUENCY OF OCCURRENCE OF DISEASES OF THE ORBIT, ACCORDING TO THE DATA OF APPEALS TO STATE INSTITUTION “THE FILATOV INSTITUTE OF EYE DISEASES AND TISSUE THERAPY OF THE NAMS OF UKRAINE” FOR 2010-2020.

Polyakova S., Chebotarov Ye.

State Institution “The Filatov Institute of Eye Diseases and Tissue Therapy of the NAMS of Ukraine” Odesa, Ukraine

Introduction: anatomical and topographic features of the orbit, its relationship with the skull cavity and paranasal sinuses, the state of the vascular system (direct connection of the arterial system of the orbit with the external and internal carotid arteries, the absence of valves in the veins of the orbit) create conditions for the development of various pathological processes that are characteristic not only for the orbit and its surrounding structures, but also for some general diseases.

Timely differential diagnosis of the pathological condition of the orbit is very difficult, meanwhile, the tactics of treatment and its final result depend on the correct diagnosis. Mistakes in establishing a diagnosis, incorrect treatment tactics can lead not only to the loss of visual functions and the eye as an organ of vision, but sometimes to the life of the patient.

Purpose: to analyze the frequency of occurrence of orbital diseases in Ukraine, according to the data of patients' appeals to the SI “The Filatov Institute of Eye Diseases and Tissue Therapy of the AMS of Ukraine” for 10 years (2010-2020).

Material and methods: 2941 treatment results of the patients with orbital diseases, who were treated at the Institute in 2010-2020, were analyzed retrospectively. The average age of the patients was 51.3±14.5 years old. There were 1949 (66.3%) women and 992 (33.7%) men. 1188 patients were operated on. There were 1016 orbitotomies and 172 orbital exenterations were performed, 5 of which were orbitosinual. Over the years of the study, the ratio of the number of women and men, as well as the average age of the patients, did not differ.

Results: the analysis of diseases of the orbit according to their genesis showed that patients with endocrine ophthalmopathy - 1005 (34.1%) cases and with inflammation of orbital tissues, both acute and chronic - 973 (33.1%) cases came to the institute most often, among which Dacryoadenitis was diagnosed in 142 (14.6%) cases. Orbital tumors accounted for 816 (27.8%) cases of all orbital diseases, among them benign - 373 (45.7%), malignant - 443 (54.3%). Cysts of various origins (dermoid, epithelial, cholesteatoma) were found in 86 (2.9%) patients. Anomalies of the development of the vascular system were observed in 12 (0.4%) cases, Wegener's disease - in 4 (0.14%), sarcoidosis - in 1 (0.03%), post-traumatic hematoma - in 1 (0.03%), heartworm disease - in 43 (1.5%).

Among benign tumors (373 patients), tumors of vascular genesis prevailed (cavernous hemangiomas – 185 (49.6%) cases). The second place was occupied by tumors of neurogenic origin (neurinoma, meningioma, neurolemoma, neurofibroma, arachnoendothelioma) – 69 (18.5%), then – benign epithelial tumors of the lacrimal gland (pleomorphic adenoma) – 57 (15.3%), fibroids (soft, solid, vascular) – 25 (6.7%), rare tumors of the orbit (osteoma, mesenchymoma, histiocytoma, xanthogranuloma, leiomyoma, embryonal tumor) – 22 (5.9%) and lymphoid hyperplasia of orbital tissues – 15 (4, 0%) cases.

Malignant tumors of the orbit (443 patients) were represented mainly by tumors of epithelial origin – 211 (47.6%). Of them, malignant tumors of the lacrimal gland (adenocarcinoma, cancer in pleomorphic adenoma, adenocystic cancer) accounted for 48 (22.8%) cases, skin cancer and cancer from paranasal sinuses with spread to orbital tissue – 163 (77.2%). In second place are malignant lymphomas of different cellular structure, which accounted for 169 (38.1%) cases. The third place was occupied by metastatic tumors – 29 (6.6%) cases, among which metastatic lesions of orbital tissue from breast cancer predominated in women, and lung and prostate cancer in men. On the fourth place – primary melanomas – 19 (4.3%). Then there are malignant tumors of vascular genesis (hemangioendothelioma, hemangiopericytoma, angiosarcoma) – 13 (2.9%) and neurogenic genesis (neuroblastoma, glioblastoma) – 2 (0.5%).

Tumor-like orbital diseases (chronic productive inflammation and endocrine ophthalmopathy) accounted for 67.2% of all diseases of the orbit and lead among them, as well as according to the data of our previous studies.

It should be noted that malignant tumors took the first place (54.3%) with a predominance of epithelial tumors (60.5%), among which cancer of the eyelids and paranasal sinuses with spread to the orbit (60.8%) is in first place.

Earlier, we noted that among malignant tumors of the orbit, the first place was occupied by tumors of lymphoid origin (29.1%), the second – metastatic tumors (23.6%), the third – eyelid cancer with spread to the orbit – 22.4%, the fourth – epithelial tumors lacrimal gland (14.0%), followed by soft tissue sarcomas of the orbit (5.5%), melanomas of the orbit (5.8%), tumors of vascular origin (1.6%) and osteosarcoma (0.8%).

Conclusion: the obtained make it possible to partially assess the incidence of orbital diseases in Ukraine, based on the data of patient appeals to the State Institution “The Filatov Institute of Eye Diseases and Tissue Therapy of the NAMS of Ukraine”.

Key words: The frequency of occurrence of diseases of the orbit, benign tumors of orbit, malignant tumors of the orbit, tumor-like orbital diseases.

ORGAN-PRESERVING TREATMENT OF CHOROIDAL MELANOMA.

Polyakova S., Chebotarov Ye., Tsukanova I., Drumi D.

State Institution "The Filatov Institute of Eye Diseases and Tissue Therapy of the NAMS of Ukraine". Odesa, Ukraine

Introduction: uveal melanoma (UM) among primary intraocular malignant neoplasms accounts for up to 90%, among oncoophthalmological pathology - 25%, and among melanomas of other localization - 15%. The most frequent localization of UM is the choroid (85-88%).

At present, the main treatment of UM is organ-sarving, which can be in the form of laser surgical techniques (photo- and laser coagulation, photodynamic therapy, thermotherapy); contact (brachytherapy) and remote (irradiation with an electron, narrow proton beam) radiation therapy; stereotaxic radiosurgery (cyber-knife and gamma-knife); surgical interventions (exoresection and endoresection); cryodestruction and their combinations.

Purpose: to study the effectiveness of treatment of choroidal melanoma (MC) with transpupillary thermotherapy according to the developed technique, both as monotherapy and in combination with Sr90/It90 brachytherapy.

Material and methods: the transpupillary thermotherapy (TTT) was performed once a day, every day, for 4 consecutive days on an ophthalmic coagulator "Iridis Quantel medical" (France) using a three-mirror Goldman or Meinster PRP lens (165, WF) with a wavelength of 810 nm in a continuous mode of radiation with a power from 200 mW to 1800 mW, with a light spot diameter of 1.25-4.0 mm, an exposure of 60 s. In the form of monotherapy, TTT was performed in 88 patients with small stage T1 MC (prominence - up to 3.0 mm, base diameter - up to 12.0 mm) and in combination with Sr90/It90 brachytherapy in 76 patients in stages T1-T4. There were 110 (67.1%) women, 54 (32.9%) men. The average age of the patients was 55.9 (SD12.8) years old, the minimum age was 21 years old, the maximum is 82 years old. The right eye was affected in 48.1% (79 patients), the left - in 51.9% of cases (85 patients).

Results: a positive result of the treatment of small stage T₁ MC according to the developed TTT method was obtained in 81 (92.05%) patients, negative - in 7 (7.95%) patients. Out of 81 patients with a positive result of treatment, complete scarring of the tumor was achieved in 81.5%, partial - in 18.5% of cases.

Among MC stages T₁-T₄, a positive result of treatment was obtained in 67 (88.2%) patients, a negative one - in 9 (11.8%). Out of 67 patients with a positive result of treatment, complete scarring of the tumor was achieved in 88.1%, partial - in 11.9% of cases.

Conclusions: the combination of TTT according to the technique developed by us with Sr90/It90 brachytherapy made it possible to obtain high efficiency (88.2%) of treatment of MC stages T₁-T₄.

The high efficiency (92.05%) of the treatment of small MC (prominence - up to 3.0 mm, diameter of the base - up to 12.0 mm) according to the TTT method developed by us allows us to offer it as a monotherapy for such tumors.

Key words: Choroidal melanoma, organ-preserving treatment, transpupillary thermotherapy (TTT), brachytherapy.

APPLICATION OF MICRO-PULSE LASER TRABECULOPLASTY (577 NM) IN PRIMARY OPEN-ANGLE GLAUCOMA

Nasinyk I.O.¹, Popova O.I. ², Zadorozhnyy O. S.¹, Kustryn T. B.¹, Korol A. R.¹

1. SI "The Filatov Institute of Eye Diseases and Tissue Therapy NAMS of Ukraine" (Odesa)

2. St. Luke's Hospital (Kropivnytskyi)

AIM. To evaluate the possibility of using micropulse trabeculoplasty with a laser with a wavelength of 577 nm in patients with primary open-angle glaucoma.

MATERIALS AND METHODS. A retrospective study of the treatment outcomes of patients with primary open-angle glaucoma who received micropulse laser trabeculoplasty from 2017 to 2023. We compared the level of intraocular pressure before the intervention, after 2 weeks and 12 weeks, as well as the regimen of drug anti-glaucoma therapy.

RESULTS. 33 patients (33 eyes) were under observation. In 29 patients (88%), the decrease in mean IOP after micropulse laser trabeculoplasty was statistically significant ($P < 0.001$). In 4 patients (12%), the results of treatment were without a statistically significant difference ($P > 0,05$). In all cases, the regimen of glaucoma medications before and after laser intervention did not change.

CONCLUSION. Micropulse laser trabeculoplasty (wavelength 577 nm) in the conducted study led to IOP compensation in 88% of patients with primary open-angle glaucoma during the observation period of 12 weeks and maintaining the regimen of instillation of anti-glaucoma drugs.

ADAKHOVSKA ANASTASIIA, BOICHUK IRYNA, KATSAN SERGII AGE-RELATED CHANGES IN REFRACTION AND AXIAL LENGTH IN PRETERM INFANTS WITH RETINOPATHY OF PREMATURITY AFTER LASER COAGULATION OF THE RETINA

SI «The Filatov Institute of Eye Diseases and Tissue Therapy of the
National Academy of Medical Sciences of Ukraine»,

49/51 Frantsuzskii Bulvar, Odesa, Ukraine

Introduction. Retinopathy of prematurity (ROP) has been one of the leading causes of childhood blindness and low vision all over the world. Children who underwent laser coagulation of the retina (LCR) due to the development of severe forms of ROP are prone to the development of various kinds of refractive errors, mostly myopia and astigmatism.

The aim to estimate dynamics of the state of refraction and axial length of eye (ALE) in preterm infants with ROP after LCR in the age aspect.

Material and Methods. The material for our study was data of ophthalmological examinations of 84 premature babies at the age of 6 months to 3 years (average age is 1.1 years) and from 3 to 8 years (average age is 5.4 years) in group of children without ROP; with ROP self-regression; with ROP, who underwent LCR. The ophthalmological examination included a standard assessment of the anterior and posterior sections of the eye, strabismus and clinical refraction; eye ultrasound (A and B scans); assessment of visual acuity (from 3 years).

Results. At the age of 6 months - 3 years, the axial length of the right and left eyes in premature babies after laser coagulation of retina was 19,65□□□□□□mm и 19,52□□□□□□mm; at the age of 3 - 8 years - 22,52□1,28 mm and 22,61□1,19 mm. Spherical equivalent in premature babies after laser coagulation of the retina at the age of 6 months - 3 years was - 0.5±3.72 in the right eye and +0.07±3.54 in the left eye; at the age of 3 - 8 years -1.91±4.87 in the right eye and -2.3±4.9 in the left eye. In children after laser coagulation of retina at the age of 6 months - 3 years in the right eye, hyperopic refraction was recorded in 59.1%, myopic - in 31.8%, in the left eye - in 59.1% and 18.2%, respectively; at the age of 3-8 years in the right eye hyperopic refraction in 50.0%, myopic - in 36.4%, in the left eye - in 50.0% and 40.9%, respectively. Astigmatism < 2 D and ≥ 2 D after laser coagulation of retina at the age of 6 months - 3 years occurred in the right eye in 22.7% and 0.0%, in the left eye - in 22.7% and 4.6%; at the age of 3-8 years in the

right eye in 36.4% and 18.2%, in the left eye – in 36.4% and 22.7%, respectively. Anisometropia among children after laser coagulation of the retina was in 22.7% cases at the age of 6 months - 3 years and 18.2% at the age of 3-8 years.

Conclusions. The axial length of eye in premature babies after laser coagulation of the retina does not differ at the age of 6 months - 3 years and 3 - 8 years ($p>0.05$). A refractive shift in the magnitude of the spherical equivalent towards myopia was established in premature babies after laser coagulation of the retina. A significant difference in the magnitude of myopic refraction among premature children after laser coagulation of the retina and children without ROP/ ROP self-regression at the age of 6 months - 3 years and 3 - 8 years ($p<0.05$) was established. There was a difference in astigmatism between the right and left eyes in premature infants after laser coagulation of the retina and children without ROP/ ROP self-regression at the age of 6 months - 3 years and 3 - 8 years ($p<0.05$). For the first time, a more frequent occurrence of anisometropia among children after laser coagulation of the retina compared children without ROP/ ROP self-regression was established ($p=0.004$; $p=0.017$).

Key words: retinopathy of prematurity, age aspect, laser coagulation.

THE APPLICATION OF SPHERICAL ORBITAL HYDROXYAPATITE IMPLANTS FOR EVISCERATION OF THE EYEBALL AFTER MINE-EXPLOSIVE INJURIES.

Chebatarov Ye., Polyakova S., Sidak-Petretskaya O., Artyomov A., Pukhlik O.

State Institution "The Filatov Institute of Eye Diseases and Tissue Therapy of the NAMS of Ukraine" Odesa, Ukraine

Introduction: according to the literature, evisceration and enucleation of the eyeball after a penetrating injury is performed in 11.6-27.0% of patients in normal times, the frequency of such interventions increases in wartime. Loss of the organ of vision leads not only to functional disorders, but also to changes in the psycho-emotional status of patients.

One of the most promising areas of health care in military conditions is the improvement of restorative treatment of patients in order to return them to society as soon as possible. Thus, the problem of cosmetic eye prosthetics is important, and its successful solution contributes to the social and professional rehabilitation of patients who lost their eyeball.

At present, military trauma and, in particular, the consequences of mine-explosive damage to the eye, are of particular relevance, where it is often not possible to determine the presence of post-traumatic changes in the tissues of the orbit, which may affect the behavior of the orbital implant. At the same time, the ophthalmic surgeon may face the problem of optimal choice not only of the implant, but also of the method and timing of implantation, and peacetime experience may not be enough to solve this problem.

Purpose: the optimization of ocular globe prosthetics (OGP) formation during evisceration after mine-explosive wounds using hydroxyapatite orbital implants.

Material and methods: the clinical part of the work is devoted to the study of the immediate and remote (up to 6 months) results of OGP formation in 44 patients after mine-explosive injury during evisceration with the use of hydroxyapatite implants.

The state of the surface of the upper eyelid was evaluated subjectively, distinguishing between small, moderate and sharply pronounced deepening of the palpebra-orbital fold. The position of the front surface of the cornea of the healthy eye and the front surface of the prosthesis was objectively assessed during mirror exophthalmometry using a Hertel exophthalmometer. Functional efficiency was determined by the degree of mobility of the prosthesis, which is measured in Hirschberg degrees.

When comparing paired samples, the Wilcoxon T-test, a non-parametric analogue of the paired Student's t-test, was used.

As an estimate of the average tendency of the sample, the average value (\bar{X}) and boundaries of the 95% confidence interval ($\pm t_{0,05} S \bar{X}$) were given in the tables.

Results and conclusions: in the immediate and long-term follow-up, 41 patients had no pronounced deepening of the palpebra-orbital fold. In 3 patients after 6 months there was a pronounced deepening of the palpebra-orbital fold. During observation, in all cases, there were no deformations and narrowing of the eye slit, in all patients,

in the early stages, the exophthalmos of the prosthesis remained from 1 to 4 mm. After 6 months, there was no exophthalmos prosthesis. There were no implant rejections during the observation period.

When evaluating the effectiveness of OGP formation during evisceration, it can be seen that the mobility of the prosthesis in the four meridians is $(138.75+16.0)^{\circ}$, 45.75 degrees more than without OGP formation $(93.0+9,2)^{\circ}$. There was also symmetry in the position of the prosthesis relative to the healthy eye. After 3 months, there was an increase in the movement volume of the prosthesis by $4-6^{\circ}$ in the sum of four meridians to $(143.2+15.1)^{\circ}$. After 6 months, the mobility indicators of the prosthesis remained stable.

In the immediate and long-term follow-up, 38 patients had no pronounced deepening of the palpebra-orbital fold. Only 6 patients had pronounced deepening of the palpebra-orbital fold after 3 months. During observation, in all cases, there were no deformations and narrowing of the eye slit, in all patients, in the early stages, the exophthalmos of the prosthesis remained from 1 to 4 mm. After 6 months, in half of the cases there was exophthalmos of the prosthesis up to 1 mm, in the other half - enophthalmos of the prosthesis up to 1 mm.

There were 3 implant rejections during the observation period. In these 3 cases, after a rather short period of time - 2-3 weeks after the operation, the implant rejection began in the form of it pushing out of the scleral cavity.

Examination of the scleral sac and orbital tissues in all cases revealed changes that were of the same type, apart from some minor pathomorphological details.

The nature of pathological changes in these 3 studied cases of implant rejection can be assessed as chronic productive nonspecific inflammation of the granulomatous type, backgrounding of the fungal mycelium elements. At the same time, it is necessary to emphasize the absence in all cases of signs of acute inflammation, so, the rejection is in no way related to the sterility of the implant material or the subsequent addition of a bacterial infection.

Based on the clinical, microbiological and pathomorphological studies, the cause of the inflammatory process in the tissues of the orbit is not the material used for the implant. In our opinion, the short period of time after the injury, the presence of foreign bodies in the tissues of the orbit (metal, plastic, glass, soil areas, etc.), fungal infection in the form of mycelium in the tissues of the orbit, which led to the inflammatory process and the implant extrusion, should be considered the cause of postoperative complications.

Thus, it is necessary to pay attention to a more careful approach in solving the question of the use of orbital implants after evisceration after mine-explosive injuries. In our opinion, delayed use of implants after an injury is advisable. If evisceration is urgently required for mine-explosive injuries, it is recommended to perform it without the use of implants, and to carry out secondary implantation after a certain time.

Key words: ocular prosthesis, ocular globe prosthetics, uveal melanoma, eye subatrophy, mine-explosive injury, implant rejections.

PARTICULARS OF THE ACTIVITY OF THE HUMAN TISSUE AND CELL BANK IN THE FIELD OF CORNEA SAMPLING AND PROCESSING, OVER ONE DECADE IN THE REPUBLIC OF ROMANIA

²Adrian Cociug, MD, PhD, Assistant Professor; ¹Macagonova Olga, MD, PhD Applicant;

³Cușnir Valeriu - MD, PhD, Professor, ^{1,2}Viorel Nacu, MD, PhD, Professor

¹Tissue Engineering and Cells Cultures Laboratory, "Nicolae Testemitanu" State University of Medicine and Pharmacy

²Tissue Bank

³Department of Ophthalmology and Optometry, "Nicolae Testemitanu" State University of Medicine and Pharmacy, Chisinau, Republic of Moldova

*Corresponding author: adriancociug77@gmail.com.

Introduction. The cornea is the window of the eye, allowing light to reach the sensory cells that allow us to see the world around us. Due to corneal damage or regenerative, infectious, dystrophic and inflammatory disorders, numerous corneal diseases lead to opacity and blindness. In the Tissues and Human cells Bank from the Republic of Moldova, corneas with a long storage period are freeze-dried ones, for a period of 2 years, and those with a short storage period are stored in culture media (Tissu „C"), dehydration (Carry „C") and transport (Eusol„C").

Material and methods. The study carried out presents the evaluation of cornea sampling, processing and validation in Tissues and Human cells Bank over the 10-year period 2013 - 2022 for 395 corneas, from 202 donors (69.8% men, 30.2% women), with an average donor age of 59.4 years (SD 18.3 years) and between 18 and 91 years. Donors were from forensic medicine (23.5%), public hospitals (67.6%) and multi-organ donors (7.1%). The most common causes of donor death were cardiovascular disease, trauma, and cerebrovascular disease. Invalidation of the cornea was in 25.4% of cases, of which they were determined by serological infections (HBsAg-positive, HCV-positive, HIV/AIDS) - 15%, and biological contamination occurred in 7.8% of the total donor cornea. In total (294 corneas), 74.6% of the processed corneal tissue was used for corneal transplantation (74.8% for penetrating keratoplasty, 2.1% for lamellar keratoplasty, and 1.3% for unspecified transplants) and 25.4% (101 corneas) were destroyed.

Results. The corneas from Tissues and Human, during the period 2013-2022, were evaluated in a macro- and microscopic study that determined 3 important groups: the first group (160 donors) up to 10 hours of the sampling from death - the most frequently determined was the anterior surface of cornea with edema of the epithelium, stroma absolutely "transparent, not thickened, rare short folds, very thin Descemetov membrane, endothelial layer is completely transparent, intact on the

entire surface. Areas with uniform redistribution of cells, preferentially at the edge of the cornea and the middle area. Density of the endothelial cells being greater than 2800 cells / mm², with the moderate signs of the polymegetism, cellular pleomorphism, being considered as indications for transfixing keratoplasty. The corneas from the second group (30 donors) - with the sampling period from 10 to 15 hours - the surface of the epithelium is slightly edematous, its integrity is not compromised (exception may be a minor mechanical desquamation). Stroma with initial signs of the edema in the lower layers, not thickened, transparent. Descemet's membrane has a single smooth plica, located centro-radially; the endothelial layer is intact. The endothelial layer is arranged uniformly, with the persistence of the mosaic, slightly tumified, which counts 26 cells in a square that forms an average of 2600 cells per mm². The corneas from group III (12 donors) with the sampling period after 15 hours - edematous anterior epithelium, in some areas exfoliated with detachment of Bowman's membrane, sometimes mosaic desquamation is observed. The stroma is edematous throughout the layer, dull in color. Descemetov membrane has pronounced folds, the folds directed in different directions like "parquet floor" or "checkerboard". The endothelial layer is matte, interrupted along the outline of the envelopes that appear transparent. Microscopically, endothelial cells reach the figure of 2000 per mm².

Conclusions. 1. The analysis of the clinical and socio-demographic factors of the donation process associated with the quality of th corneal tissue showed the importance of implementing Tissues and Human cells Bank quality control programs, in order to promote the selection of good quality corneal tissues and guarantee a donation process with donor identification mechanisms , extraction, preservation and distribution of corneal tissue guided by best practices that aim to minimize the risk of the compromising tissue quality.

2. The quality of the corneal tissue is a fundamental factor for the success of transplantation and to guarantee good quality tissues, it is important that the time limits between death and enucleation, death and preservation, and enucleation and preservation are established by the Tissues and Human cells Bank, in order to minimize the risks to which tissues are exposed due to chronological factors related to the sampling process.

3. The best quality of the cornea is that of group I, which had a sampling time of up to 10 hours, which defined the density of the endothelial cells as 2800 cells / mm², with moderate signs of polymegetism, cellular pleomorphism, being considered as the indications for transfixing keratoplasty.

SURGICAL FEATURES IN DIABETIC RETINOPATHY

Vitalie Cuşnir, Nicolae Bobescu

Department of Ophthalmology and Optometry, State University of Medicine and Pharmacy "Nicolae Testemiţanu", Chisinau, Republic of Moldova

Introduction. Eye surgery has progressed a lot in last years, so that modern treatment methods allow a minimally invasive intravitreal approach through 3 27G trocars. Advances in surgical techniques have allowed the improvement of the most complex clinical cases. The gold standard for solving diabetes complications is posterior vitrectomy.

Material şi methods. The bibliographic sources from the PubMed and Google Scholar databases were analyzed, using the key words: diabetic retinopathy, vitrectomy, ophthalmic surgery, and approximately 350 articles were selected. The final bibliography contains 50 relevant sources, which were considered representative.

Results. Pars plana vitrectomy has proven to be the most effective method to treat complicated cases of diabetic retinopathy in the last decade. During the intervention, panretinal laser photocoagulation is performed together with the injection of anti-VEGF and steroids to reduce the processes of angiogenesis and macular edema. The development of minimally invasive vitrectomy and the integration of the 23G, 25G and 27G systems into clinical practice has revolutionized surgical treatment into a safer, more efficient and faster one. The lack of conjunctival sutures at the end of the intervention greatly improved the comfort and recovery of the patients. Reducing the size of the instruments and increasing the number of cuts makes vitrectomy effective in the most complicated cases. Unlike 20G surgery, currently, the vitreotome is a multifunctional tool, being used for aspiration, cutting, segmentation and removal of fibrovascular membranes. The most common intraoperative complications associated with posterior vitrectomy are iatrogenic macular holes and hemorrhages. Iatrogenic macular holes usually appear during peeling of the epiretinal membranes, close to the vitreoretinal tractions and there must be good coagulation around. Hemorrhages due to direct damage to blood vessels are rare, often occur when segmenting membranes with neovessels and are well controlled by diathermy.

Conclusions. Remarkable advances have been made in diabetic retinopathy surgery in recent years. The minimally invasive intravitreal approach reduced the complication rate. Pars plana vitrectomy is a very effective method. The association of vitrectomy with intraocular injection of anti-VEGF and steroids, photocoagulation and diathermy has demonstrated positive intra- and postoperative results.

THE CHALLENGE OF RETINITIS PIGMENTOSA

**Cușnir Valeriu, Dumbrăveanu Lilia, Bobescu Doina, Bîlba Rodica,
Cușnir Vitalie, Bobescu Nicolae, Șontea Ana**

**Ophthalmology and Optometry Department, SUMP „Nicolae Testemițanu”,
Chișinău**

Retinitis pigmentosa (RP) is a genetic pathology, which causes a gradual and irreversible decrease in visual acuity. More than 3000 mutations in more than 80 distinct genes or loci have been implicated as causes of RP. These mutations can be transmitted as an autosomal dominant (30-40%), autosomal-recessive (50-60%) or X-linked (5-15%).

Although the main cause of RP is genetic mutations, studies has shown that the inflammatory component has an important role in the progression of the disease. Due to abnormal activation of immune factors, permanent inflammation results in cell loss and structural destruction. At the same time, the elements and mechanisms that directly lead to the degeneration of photoreceptors in RP were determined, such as: trophic factors, oxidative stress and microglial activation.

Oxidative stress has an important role in cone degeneration in RP. High oxygen levels cause the activation of nicotinamide adenine dinucleotide phosphate (NADPH), which increases the production of superoxide radicals, which can deteriorate cones and rods.

In 2004, Leveillard et al. identified a trophic factor produced by healthy rods that promotes cone survival. This factor was called the rod-derived cone viability factor (RdCVF). Thus, the downstream effects of the trophic factor RdCVF are to increase energy availability in the cones.

Early rod degeneration is thought to trigger microglial activation in RP, which may contribute to subsequent cone death. Microglial activation has been observed in the inner and outer nuclear layers and the subretinal space in RP patients.

Globally, there are currently 131 drugs reported in all stages of clinical development for RP, including 80 drugs in preclinical development and 30 drugs in advanced clinical development. Of the 65 ATMPs in development, 10 are cell therapies (15.4%), 52 are gene therapies (80%) and 3 are genetically engineered cell therapies (4.6%).

Conclusion: Retinitis pigmentosa is a disabling pathology that requires a multidisciplinary approach. The research and elucidation of the pathogenetic mechanisms that lead to the appearance of Retinitis Pigmentosa can determine the stopping of the progression as well as the prevention of its complications, and the latest cellular and genetic therapies require implementation.

TRATAMENTUL CONSERVATOR CONTEMPORAN AL RETINOPATIEI DIABETICE

USMF “Nicolae Testemițanu”, Catedra Oftalmologie și Optometrie

Cușnir Vitalie, Draganel Cristina, Dumbrăveanu Lilia, Cușnir Valeriu

Tratamentul conservator al RD a fost și este unul din compartimentele contradictorii ale oftalmologiei contemporane. În anii 1990, introducerea în uz a anumitor medicamente a îmbunătățit rezistența mecanică a pereților capilari și scăderea permeabilității acestora, cum ar fi dobesilatul de calciu sau vinpocetina, dar în anii următori impactul lor biologic în DZ nu a fost confirmat prin investigații solide.

Necătînd la istoricul lung de experimentare și investigații clinice unele preparate rămîn totuși de elecție și aparent eficiente, cum ar fi:

1. Emoxipina (metiletilperidinol 1%)
2. Xantinol Nicotinat / soluție injectabilă 15%

Aceste remedii farmacologice continuă să fie utilizate și în prezent pentru a trata hemoragiile subconjunctivale și intraoculare, angioretinopatiile, neuropatiile ischemice optice non-arteritice, angiopatiile diabetice, retinopatiile. Se investighează o nouă moleculă, Nicotinat de 2-etil-3-hidroxi-6-metilpiridină, care include doi farmacofori: 3-hidroxipiridină și nicotinat. Prezența 3-hidroxipiridinei oferă un complex de efecte antioxidante și membranoprotector. Xantinol nicotinat dilată vasele periferice, îmbunătățește microcirculația în vasele retiniene și inhibă agregarea trombocitelor.

Tratamentul medicamentos are ca scop restabilirea integrității peretelui vascular (structura și funcția endoteliului și a membranei bazale a vaselor retiniene deteriorate), reducerea microtrombozei (îmbunătățirea microcirculației), prevenirea dezvoltării zonelor de ischemie retiniană și producerea de factor vasoproliferativ, reducerea riscului de apariție a vaselor nou formate și reducerea și/sau eliminarea completă a edemului macular.

În prezent sunt disponibile multe dovezi pentru implant de dexametazon sau fluorochinolon intravitreal. Totodată dovezile sunt limitate și inconsecvente pentru compararea dexametazonei cu antiVEGF. Agenții antiVEGF utilizați în oftalmologie include Bevacizumab (Avastin), Pegaptanib (Macugen), Ranibizumab (Lucentis), Aflibercept (Trap- Eye).

Ranibizumab se leagă cu mai mare afinitate de toate izoformele solubile ale VEGF-A și are greutate moleculară mica -48 kDa (Bevacizumab -149 kDa), adică de 3 ori mai mica decît Bevacizumab și timpul său de înjumătățire intravitreal este cu 75% mai scurt.

Sunt efectuate studii (Review Nr. 5, 2022) ce privesc angiopectinele. Ang-2 și VEGF-A conduc în mod sinergic la scurgeri vasculare, neovascularizare și inflamație, componente cheie ale bolilor vasculare retiniene. În prezent, calea Ang-1/Tie-2 (angiopietina-1 se leagă și fosforilează receptorul Tie2) este o țintă terapeutică promițătoare pentru bolile vasculare retiniene. Faricimab este primul anticorp monoclonal bispecific pentru utilizare intravitreală care poate neutraliza VEGF și Ang-2. Datorită activității prelungite, faricimab permite extinderea intervalului dintre injecțiile succesive până la trei sau patru luni la pacienții cu RD

Concluzii: Indiscutabil toți pacienții cu RD necesită tratament specializat la oftalmolog, observație și tratament la endocrinolog. Tot odată, periodic se schimbă tactica în privința indicațiilor vitrectomiei, așa ca hemoragiile vitreene, RDP, EM și decolarea tracțională maculară și/sau retiniană.

Tratamentul RD este destul de complex, necatînd la faptul că cel conservator nu este atît de elocvent și pe deplin studiat, deoarece astfel de studii necesită timp destul de îndelungat.

Cele menționate mai sus ne sugerează idea de elaborare a unor metode complexe sau/și a unei tactici de conduită și tratament care vor permite restabilirea parțială sau ameliorarea funcțiilor vizuale.

EASILY WITH GLAUCOMA ON THE STAIRS

Vasile Potop*

Glaucoma comprises a group of diseases having in common a chronic, progressive and multifactorial optic neuropathy.

Glaucoma treatment, in turn has a chronic, progressive and diversified therapeutic modality; from topical treatment, to laser treatment, filtering operations or artificial drainage systems.

The treatment methods follow a certain sequence, from simple to complex as the method itself or as potential complications.

The succession of glaucoma therapeutic modalities can constitute the set of therapeutic stairs of glaucoma.

The more advanced the disease, the more vulnerable the retinal ganglion cells are. *Easily with glaucoma on stairs* recommends increased attention to the moments of passage from one modality of treatment to another modality. Not too early but not too late, not too sharp but not too tempered.

*Professor of Ophthalmology at University of Medicine and Pharmacy Carol Davila Bucharest

