



The Effectiveness of Radiowave Surgery in the Treatment of Patients with Melanoma of Iris, Ciliary Body and Choroid

A. Maletsky¹ and O. Khomyakova^{1*}

¹Institute of Ophthalmic Diseases and Tissue Therapy, V.P. Filatov of NAMS of Ukraine, Odessa, Ukraine.

Authors' contributions

This work was carried out in collaboration between both authors. Author AM designed the study, wrote the protocol and wrote the first draft of the manuscript. Author OK performed the statistical analysis, managed the literature searches and prepared final draft of the manuscript. Both authors read and approved the final manuscript.

Article Information

DOI: 10.9734/OR/2020/v12i230143

Editor(s):

(1) Dr. Ahmad M. Mansour, American University of Beirut, Lebanon.

Reviewers:

(1) Asaad Ahmed Ghanem, Mansoura University, Egypt.

(2) Brian Joondeph, USA.

Complete Peer review History: <http://www.sdiarticle4.com/review-history/56131>

Received 09 February 2020

Accepted 15 April 2020

Published 21 April 2020

Original Research Article

ABSTRACT

The purpose of the study was to investigate the effectiveness of radiowave surgery in the treatment of uveal melanoma.

Materials and Methods: The study was performed on the basis of the oncoophthalmology department of the State Institution «Institute of Eye Diseases and Tissue Therapy named by academician V.P. Filatov of the NAMS of Ukraine» during 2009-2019.

Treatment with radio wave knife "Surgitron" manufactured by "Ellman International", was performed in 71 patients with melanoma of the iridociliary and chorioid (mean age 55.7 ± 1.6 years, minimum age 20 years, maximum age 77 years, Me (25%, 75%) = 59.0 (46.0; 65.0)). These patients were split into two groups: 45 (61.6%) patients with melanoma localization in the iris and ciliary body (I group) and 28 (38.4%) patients with melanoma mostly affecting the ciliary body and choroidea (II group). In patients with melanoma of the ciliary choroidal region, a 40-day course of external β -therapy (Sr90+Y90) was performed (25-30', RD = 40 Gy, LAD = 400 Gy). The follow-up period after the intervention was 10 years. Statistical analysis was performed by analysis of variance using Statistica 13.0 software (Dell StatSoft Inc, USA).

*Corresponding author: E-mail: khomiakova.ov@gmail.com;

Results and Discussion: The use of a radio wave knife in resection of the UM allowed to maintain the ascending visual acuity in 100% operated for 12 months. The frequency of eye subatrophy in the subsequent stages of observation did not exceed 5%. The frequency of tumor recurrence when using a radio wave knife within 24 months of observation does not exceed 15%. The incidence of postoperative complications with the use of a radio wave knife does not exceed 5%. Low incidence of complications and recurrences, better five-year survival rate using radiowave surgical method allows to recommend it for wide use in combined treatment of uveal melanoma.

Conclusion: Radiowave knife is safe and clinically effective method of surgical treatment of uveal melanoma.

Keywords: Uveal melanoma; radiowave knife; treatment; efficacy.

1. INTRODUCTION

Uveal melanoma (UM) is a rare oncopathology, but it is most common amongst primary eye malignancies in adults. It is estimated that more than 7,000 cases of UM per year are registered worldwide, with an average standardized age-related morbidity rate of 4.3 per million [1,2]. This malignant formation is equally common in men and women alike [2]. Europeans account for 98% of cases, Latin Americans - about 1%, and for Asians, Africans and Native Americans the incidence rate is less than 1%. UM is usually diagnosed in patients aged 50-60 years, with an average age in most cases equal to 55 years [1, 2]. The incidence rate has been shown to increase with age, reaching a maximum of 70-75 years, and then stabilizing [1].

It should be noted that in 90% of cases melanoma affects the choroid, in 6% of the ciliary body and in 4% - the iris. The primary melanoma of the trabecular mesh ring and iris melanoma with an icy structure are less common [3,4].

UM therapy depends on the size of the tumor, its location, clinical properties, the status of the other eye, the systemic condition of the patient and the needs of the patient. Treatment options include transpupillary thermotherapy, brachytherapy, charged particle irradiation, stereotaxic radiation therapy, local resection, enucleation and orbital exenteration [5].

Our experience with photodestruction and local radiotherapy in melanoma of the iridociliary zone and peripheral part of the choroid has shown that it is not always possible to avoid such complications as secondary glaucoma, post-radiation cataracts, scleromalacia and several other complications [6]. Surgical removal of the tumor in the pre-equatorial region does not always allow to avoid such intraoperative complications as expulsive bleeding, partial

hemophthalmos, retinal detachment and postoperative complications, such as cataracts, subatrophy of the eye, etc. [5,6].

Analyzing the causes of operative and postoperative complications in the removal of melanoma located in the pre-equatorial region, we conclude that they arise due to the technique of surgery. So, first of all, when you remove a tumor by traditional methods, bleeding is possible, which is difficult to stop. Secondly, the simultaneous removal of the tumor and local brachytherapy increases the therapeutic load on the eye, which leads to hypotension and subatrophy of the eye [6].

Based on the above, we can conclude that the reduction of the percentage of these complications can be achieved by simultaneous removal of the tumor and coagulation of blood vessels, for example with the help of a radio wave knife [7] and with the location of the main tumor node in the choroid - to carry out local β -therapy in advance, - to conduct a lamellar sclerochorioidectomy. This will not only reduce the traumatic effect on the eyeball, but also adhere to the principle of elasticity and reduce the risk of bleeding during surgery by partially running vessels after brachytherapy.

In recent years, in ophthalmic surgery, there was implemented the radio wave method of incision and coagulation of soft tissues using high-frequency radio waves (3.8-4.0 MHz). The dissecting effect is achieved due to the heat generated by the resistance of tissues to the penetration of directed high-frequency waves into them. High-frequency energy is concentrated on the tip of the "active" or "surgical" electrode and causes a surge in intracellular molecular energy, which heats the tissues and actually vaporizes the cells. In this case, there is no direct contact of the electrode with cells, and the electrode itself does not heat up. This technique is gentle, tissue

damage when exposed to a radio wave knife is several times less than when using any other electrosurgical instrument [8-12].

In implementing the planned technology of organ-preserving treatment for melanoma of the iridociliary and ciliary choroid regions, we have encountered a number of questions that we have not found answers in the professional literature. In particular, data on the use of radiowave surgery for melanoma iridociliary and ciliary choroidal areas, in the available literature was not found, therefore, there are no rational modes and optimal power of the Surgitron knife when manipulating the sclera, iris and choroid.

The purpose of the study was to investigate the effectiveness of radiowave surgery in the treatment of uveal melanoma.

2. MATERIALS AND METHODS

The study was performed on the basis of the oncoophthalmology department of the State Institution «Institute of Eye Diseases and Tissue Therapy named by academician V.P. Filatov of the NAMS of Ukraine» during 2009-2019.

Treatment with radio wave knife "Surgitron" manufactured by "Ellman International", was performed in 71 patients with melanoma of the iridociliary and choroid (mean age 55.7 ± 1.6 years, minimum age 20 years, maximum age 77 years, Me (25%, 75%) = 59.0 (46.0; 65.0).

2.1 Inclusion Criteria

Adult patients with verified UM, the size of tumor base ≤ 10 mm, I-II stage by AJCC [13], signed ICF.

2.2 Exclusion Criteria

Extraorbital growth, the size of tumor base > 10 mm, metastatic lesions, other cancers, severe comorbid pathology (stroke, heart failure, renal failure, hepatic failure etc).

All patients were examined using following methods: visometry, perimetry, biomicroscopy, ophthalmoscopy, gonioscopy, sonography, diaphanoscopy [14] Due to the fact that the localization of melanoma of the anterior segment of the eye was different and, therefore, the tactics of treatment were different in this regard, we considered it appropriate to divide patients into two groups.

The first group consisted of 45 (61.6%) patients with melanoma localization in the iris and ciliary body. The second group consisted of 28 (38.4%) patients with melanoma mostly affecting the ciliary body and choroidea.

In patients with melanoma of the ciliary choroidal region, a 40-day course of external β -therapy (Sr90+Y90) was performed according to the following procedure: a suitable applicator, depending on the size of the tumor and its localization, is selected under local anesthesia, depending on the size of the tumor and its exposure, 25 -30 minutes, SD = 40 Gy, TAD = 400 Gy [15].

The surgical field was treated with an alcohol solution of chlorhexidine. A palpebral dilatator was applied. A section of the conjunctiva of the sclera in the projection of the tumor along the limb, a deviation from it of 4-7 mm (depending on the location of the tumor) and separation from the eyeball. After hemostasis. A layered scleral incision was made. An isolated tumors of the iris and ciliary body, the choroid, were removed with the help of a radio-wave electric knife, than biosamples were sent for histopathological examination. Nodal sutures were imposed on the scleral incision, the anterior chamber was washed with Ringer's solution, the conjunctiva was sutured with a continuous silk suture. After surgery isinfectant drops, dexamethasone and cefazolin were administrated, with aseptic dressing. All surgical interventions were performed by the authors.

The follow-up period after the intervention was 10 years.

Statistical analysis was performed by analysis of variance using Statistica 13.0 software (Dell StatSoft Inc, USA) [16].

3. RESEARCH RESULTS

At the time of initiation of treatment, the mean values of tumor prominence were 4.3 ± 0.3 mm with a length of 8.3 ± 0.4 mm, which corresponds to a tumor volume of 19.0 ± 0.7 mm³ (Table 1).

There were no statistically significant differences in these indices between the tumors of the rectociliary and the celiochoroid areas ($p > 0.05$). Visual acuity in the diseased eye averaged 0.4 ± 0.04 .

No surgical complications were noted in any patient with uveal melanoma. In the early

postoperative period (24 hours later), in one case (1.4%), there was a local retinal detachment, which was absent after 4 months at examination. All 26 patients who had visual acuity from 0.1 to 1.0 before surgery were able to maintain it. It should be noted that 15 (20.5%) patients before surgery had reduced vision due to lens opacities and impaired regulation of intraocular pressure. There were no cases of radiation reactions after brachytherapy, the average absorbed dose was 408.6 ± 5.7 Gy. After 4 months in 3 (4.1%) cases corneal dystrophy was observed in the initial stage.

With regard to visual acuity, our study showed that during the first year it was not decreased in both clinical groups (Fig. 1).

Tumor relapse was observed in 4 (8.9%) cases in group II (Table 2) after one year, two and two and a half years. Subsequently, these patients underwent enucleation of the eye.

No deaths were reported in either group, but at the end of the follow-up period only 30.1% of the original sample were available for contact.

No cases of metastatic lesions were detected thus radiowave method could be accepted as safe and effective for surgical treatment of UM.

4. DISCUSSION

According to the literature, the mortality rate from ΓM with isolated use of brachytherapy averages 10% over 5 years and 18% over 10 years. Applique technology does not always give the optimum result, because with tumor thickness greater than 5 mm, local recurrences are not likely to occur. Complications of brachytherapy include cataracts, radiation retinopathy and opticopathy, maculopathy, neovascular glaucoma, and exudative tumor remission [5].

Table 1. The geometric characteristics of tumors in the clinical groups

Parameters	I group (n=45)	II group (n=28)
Prominence, mm	$4,3 \pm 0.3$	$4,2 \pm 0.4$
Length, mm	8.2 ± 0.3	8.4 ± 0.5
Volume, mm ³	$18,9 \pm 0.6$	19.4 ± 0.8

Table 2. Late complications in the clinical groups

Indices	I group (n=45)		II group (n=28)	
	Abs.	%	Abs.	%
Subatrophy	2	4.4	1	3.6
Relapses	-	-	4	14.3

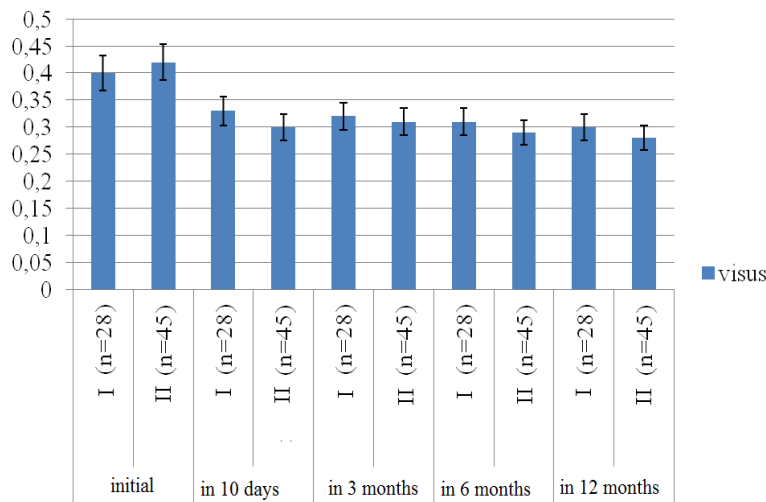


Fig. 1. Dynamics of visual acuity in patients in both clinical groups

In recent years, organ-saving treatment has become increasingly popular compared to enucleation. Local resection is an alternative way to treat patients with iris, ciliary and choroidal melanoma. At present, not all surgeons do chorioidectomy because of technical difficulties. Tumors can be removed surgically by transretinal (endorection) or transscleral (exorection). If both methods are used, complications such as retinal detachment and hemorrhage into the vitreous may occur [1,5].

During the first five years after surgery, all patients in the main group were alive. The relapse rate in the main group did not exceed 15% cases. In our opinion, such effect can be explained by a decrease in the dissemination of tumor cells using the electro-surgical method. According to the literature, five-year survival with UM (without metastasis) is about 75% [6], so the achieved levels are satisfactory.

5. CONCLUSION

Direct (visual functions, postoperative clinical course) and long-term results (visual functions, optical media, IOP, tumor recurrence) in patients with resection of the iridociliary and ciliary choroidal region using high-frequency current from generations 3.8-4.0 were studied. High-frequency radio-wave surgery has reduced the risk of intraoperative and postoperative complications and, therefore, to maintain high visual functions.

DISCLAIMER

The products used for this research are commonly and predominantly use products in our area of research and country. There is absolutely no conflict of interest between the authors and producers of the products because we do not intend to use these products as an avenue for any litigation but for the advancement of knowledge. Also, the research was not funded by the producing company rather it was funded by personal efforts of the authors.

CONSENT

As per international standard written participant consent has been collected and preserved by the authors.

ETHICAL APPROVAL

As per international standard informed and written ethical permission has been collected and preserved by the author(s).

COMPETING INTERESTS

Authors have declared that no competing interests exist.

REFERENCES

1. Aronow ME, Topham AK, Singh AD. Uveal melanoma: 5-year update on incidence, Treatment and Survival (SEER 1973-2013). *Ocul Oncol Pathol.* 2018;4(3):145-151.
2. Rao YJ, Sein J, Badiyan S, Schwarz JK, DeWees T, Grigsby P, Rao PK. Patterns of care and survival outcomes after treatment for uveal melanoma in the post-coms era (2004-2013): A surveillance, epidemiology, and end results analysis. *J Contemp Brachytherapy.* 2017;9(5):453-465
3. Yang J, Manson DK, Marr BP, Carvajal RD. Treatment of uveal melanoma: Where are we now? *Ther Adv Med Oncol.* 2018; 10:1758834018757175.
4. Shields CL, Kaliki S, Furuta M, Fulco E, Alarcon C, Shields JA. American Joint Committee on Cancer Classification of Uveal Melanoma (Anatomic stage) Predicts Prognosis in 7,731 Patients: The 2013 Zimmerman Lecture. *Ophthalmology.* 2015;122(6):1180-6.
5. Kim JH, Shin SJ, Heo SJ, Choe EA, Kim CG, Jung M, Keum KC, Yoon JS, Lee SC, Shin SJ. Prognoses and clinical outcomes of primary and recurrent uveal melanoma. *Cancer Res Treat;* 2017. DOI: 10.4143/crt.2017.534
6. Chua V, Aplin AE. Novel therapeutic strategies and targets in advanced uveal melanoma. *Curr Opin Oncol.* 2018;30(2): 134-141.
7. Ji MJ, Lee SJ, Han SB, Hyon JY. Efficacy and safety of conjunctival cystectomy using high-frequency radiowave electro-surgery: A preliminary report. *Eye Contact Lens.* 2019 Nov;45(6):410-413.
8. Choi SM, Jin KH, Kim TG. Successful treatment of conjunctival lymphangiectasia accompanied by corneal dellen using a high-frequency radiowave electro-surgical device. *Indian J Ophthalmol.* 2019;67(3): 409-411
9. Khomyakova OV, Vit VV, Maletskyi AP. Comparing structural changes in the rabbit's uveal tract after the use of a radiowave surgery unit versus a cutting tool. *J. Ophthalmol. (Ukraine).* 2019;4:43-48

10. Luzyanina VV. [Diagnosis and treatment of neoplasms of the organ of vision in the Primorskiy centre of eye microsurgery] Pacific Medical Journal. 2017;2:21-25 [Rus].
11. Lukáts O, Németh J. Ellman surgitron IEC rádiófrekvenciás készülékkel végzett műtéink tapasztalatai A Magyar szemorvostársaság. Évi kongresszusa; 2013.
Available: <https://adoc.tips/queue/a-m-a-g-y-a-r-s-z-e-m-o-r-v-r-o-s-s-a-s-t-a-g-e-v-i-k-o-n-g-.html>
12. Patent RU 2265423 МПК. А61F 9/007 (2000.01) [Method for radiosurgical treatment of uveal melanoblastoma] Inventors: Smolyakova GP (RU), Pikhovskaya I.G. (RU), V. Luzyanina (RU), Sorokin E.L. (RU) Patentee: Far Eastern State Medical University; 2005.
13. Keung EZ, Gershenwald JE. The eighth edition American Joint Committee on Cancer (AJCC) melanoma staging system: Implications for melanoma treatment and care. Expert Rev Anticancer Ther. 2018;18(8):775-784.
14. Kanski's Clinical Ophthalmology: A Systematic Approach 8th Edition/by Jack J. Kanski MD MS FRCS FRCOphth, Brad Bowling FRCSEd(Ophth) FRCOphth FRANZCO Saunders Ltd.; 8 edition. 2015;928.
15. Belaïd A, Nasr Ch, Jmour O, Cherif A, Kochbati L, Bouguila H, Besbes M, Benna F. Brachytherapy of uveal melanomas with ruthenium-106 plaques. Asian Pac J Cancer Prev. 2016;17(12):5281-5285.
16. Rebrova OYU. [Statistical analysis of medical data. Application of the STATISTICA software package]. Media Sfera. 2002;312.

© 2020 Maletsky and Khomyakova; This is an Open Access article distributed under the terms of the Creative Commons Attribution License (<http://creativecommons.org/licenses/by/4.0>), which permits unrestricted use, distribution, and reproduction in any medium, provided the original work is properly cited.

Peer-review history:

*The peer review history for this paper can be accessed here:
<http://www.sdiarticle4.com/review-history/56131>*